

## Full length article

## The new etiology and surgical therapy of stress urinary incontinence in women



Adam Ostrzenski

Institute of Gynecology, Inc., 7001 Central Ave., St. Petersburg, FL, 33710, USA

## ARTICLE INFO

## Article history:

Received 17 April 2019

Received in revised form 16 November 2019

Accepted 20 November 2019

## Keywords:

Stress urinary incontinence  
SUI  
Urethral stabilization procedure  
Urethral stabilizing mechanism  
SUI therapy  
Micturition  
SUI integral theory  
SUI hammock hypothesis  
SUI etiology

## ABSTRACT

**Objectives:** To determine the subjective and objective cure rate of a urethral stabilization procedure (USP) for stress urinary incontinence (SUI) in women; to describe this new surgical intervention; to record its potential complications; to establish the SUI etiology.

**Study Design:** The author conducted a prospective case series study in ambulatory settings and under local anesthesia. Thirty-four consecutive women with uncomplicated SUI subjected to USP, which was performed by reconstructing site-specific defects within the urethral stabilizing mechanism (USM) and using no surgical slings, meshes or absorbable sutures. The paravaginal defect(s) was repaired by transvaginal approach. The endopelvic fascia was sharply separated from the ventral perineal membrane (VPM) just above the anterior urethral meatus. The vestibular bulbs sharply dissected from VPM and advance upwards. The VPM defect(s) reconstructed and vestibular bulbs placed back to the original location. The access to the peri- and the para-urethral region was created by making a lateral vertical incision, aside from the lateral urethral meatus and defects were repaired. The suburethral transverse incision was made beneath the urethral meatus and the stratum-by-stratum surgical dissection conducted until the lateral vaginourethral ligament is visualized bilaterally. The defect(s) within the vaginourethral ligaments was surgically reconstructed, and the vaginal wall repaired. The primary outcome measured subjective and objective cure rates, and the secondary outcome measured the occurrence of potential complications. The five-year postoperative follow-up was conducted.

**Results:** Two out of thirty-four patients dropped-out from the study. The USP performed without difficulties, and no severe complication observed. One-subject developed superficial wound separation (3.1 %) and one-subject (3.1 %) developed urinary urge incontinence at the 5-postoperative-year. At 60-month follow-up subjective and objective cure rates were a 92 % and an 88 % respectively.

**Conclusions:** The urethral stabilization procedure yields a high degree of subjective and objective cure rates without severe complications and is a well-tolerated operation by women. The urethral stabilization procedure is a simple, easy to implement, and reproducible method for uncomplicated stress urinary incontinence in women. Site-specific defects within the urethral stabilizing mechanism constitute the etiology of the stress urinary incontinence in women.

© 2019 Elsevier B.V. All rights reserved.

## Introduction

The recommendation for the initial surgical therapy of uncomplicated stress urinary incontinence (SUI) in women is a midurethral sling [1–4]. Slings, meshes, and nonabsorbable sutures themselves can cause severe complications [1,5–8]. Recently, the use of surgical meshes and tapes to treat SUI or urogynecologic prolapse was suspended by the UK National Health Service [9]. Due to severe complications, the US Federal Drugs Administration (FDA) ordered to stop manufacturing, to use, and to

distribute surgical mesh implants intended for anterior vaginal wall reconstruction [10].

Petros et al. and DeLancey postulated that complex anatomical structures interact together to maintain urinary continence [11,12]. However, clinical-scientific researchers who conducted their investigations on the urethral anatomy evaluated only fragments of the urethral stabilizing mechanism (USM) [11–15]. Ostrzenski examined the urethral anatomy and established the occurrences of the defects within USM [16].

The hypothesis was advanced that reconstructions of all identifiable anatomical defects within the USM could cure or improve uncomplicated SUI in women. Objectives were to determine subjective and objective cure rates of USP; to describe

E-mail address: [ao@baymedical.com](mailto:ao@baymedical.com) (A. Ostrzenski).

a step-by-step technique of USP; to ascertain the clinical implementation of USP without using slings, meshes or nonabsorbable sutures; to record complications; and to establish the etiology of SUI.

## Materials and methods

The Ethics Committee approved the USP rehearsal on human fresh female cadavers and an actual surgery on living female patients (AKBE 146/12) and both executed between November 2012 and November 2013. The follow-up conducted from November 2013 to November 2018.

Both, manual and electronic searches of the literature have been carried out from January 1800 to March 2018 using Medical Subject Headings (MeSH), which were selected and used in a search on ISI Web of Science (including conferences proceedings), PubMed, ACOGNET, ProQuest, OVID, Cochrane Collection, the Lancet onLine Collection, MDConsultant, New England Journal of Medicine, American College of Physician onLine Resources, Highwire Journal, and Citation Index websites were searched for references. The following keywords were used: urethral anatomy in women; urinary incontinence theories in women; urinary incontinence hypothesis in women; stress urinary incontinence etiology in women; stress urinary incontinence pathophysiology in women; urinary continence in women; urethral stabilizing mechanism; urethral stabilizing mechanism defects; SUI in women; urethral suspension; urethral support; urethral morphology; micturition; voiding; urethral histology; urethral pathomorphology.

### *Clinical diagnosis of uncomplicated stress urinary incontinence (SUI)*

The urologic and gynecologic societies recommend, and the current study includes, the following diagnostic clinical approach for the diagnosis of uncomplicated SUI: a) demonstrating urine leakage by utilizing a provoked cough stress test; b) establishing urethral hypermobility determined by the Q-tip test (fewer than 30 degrees rules out urethra hypermobility); c) demonstrating postvoid residual urine volume less than 150 mL is considered as an expected norm [1–4,17,18].

A multiplanar, high-resolution MRI technology assists to conduct a dynamic study and to verify the presence of anatomical site-specific defects within the USM [19,20]. Preoperatively, MRI confirmed the clinical diagnosis of site-specific defects within USM and at the six-month postoperatively determined surgical outcomes of USP.

### *Exposure*

The urethral stabilization procedure was the primary exposure. The patients were subjected to a step-by-step surgical intervention of USP without using slings, meshes or nonabsorbable sutures. USP complications were recorded.

### *Study design and patient population*

The author designed and conducted a case series study with a five-year postoperative follow-up. Performing clinical evaluation at 3-month, 6-month, 12-months, 36-months, and 60-months. Preoperatively and postoperatively, subjects charted the number of incontinent episodes within 24-hs. The validated instrument of Patient Global Impression of Improvement (PGI-I) measured the subjective cure rate; The Patient Global Impression of Severity Incontinence scale (PGI-S) measured changes in the perceived severity female stress incontinence; The Incontinence Impact Quality of Life questionnaire (IIQ-7) were used to evaluate the quality of life [21–23].

A standardized evaluation chart was created and based on the American Urological Association (AUA) recommendation and used at the baseline and during follow-up evaluations [1]. The chart included: adverse intraoperative events, short-, and long-term postoperative complications, identifications of neighboring anatomical structures, access to the surgical fields, type of sutures used, estimated blood loss, hematoma formation, persistent postoperative SUI symptoms, new urinary urge or mixed urinary incontinence, continuous urine leakage, urinary retention, reoperation, wound separation or wound dehiscence, vascular, neurological, infectious, general medical conditions, and death. The absence of urine leakage determined the objective cure rate during a cough stress test with the full bladder volume at 300 mL. A cough stress test performed on a patient in the dorsal lithotomy and standing positions.

The access to the Retzius space was accomplished through an existing perineal membrane defect and evaluation was caring out with a small flexible endoscope. Elevating the anterior suprapubic abdominal wall manually helps in better visualization and identification of the defects.

### *Inclusion criteria*

Those consecutive subjects who presented with uncomplicated SUI and failed pelvic floor physiotherapy were included. Those patients who suffer from uncomplicated SUI combined with urogenital prolapse up to stage 2 (standard POP-Q evaluation) were also included.

### *Exclusion criteria*

Those women who presented with urinary urgency, mixed urinary incontinence, incomplete bladder emptying, urine retention, transient urinary incontinence, continuous urine leakage, physical impairment, cognitive impairment, received anti-incontinence or pelvic surgery, pelvic radiation therapy, the presence of vaginal wall bulging beyond the hymen, the absence of urethral hypermobility, postvoid residual urine volume more than 150 mL, recurrent urinary tract infection, hematuria, medical condition(s) affecting lower urinary tract functions, the presence of genitourinary anatomical abnormality, taking prescription or over-the-counter medications affecting bladder or urethral functions (antimuscarinics or Duloxetine for SUI) were excluded.

### *Informed consent*

Before the urethral stabilization procedure, each subject was educated on the new USP surgical intervention, which included the following information a) USP is a new operation for SUI; b) the surgeon will perform the USP for the first time; c) the USP was designed to cure uncomplicated SUI; d) the USP potential complications explained; e) risks and benefits of surgery explained. Each and any question were answered, and informed consent presented in writing.

Each woman granted permission in writing to participate in this clinical-scientific research and allowed taking digital photographs. Additionally, a witness verified and signed the document.

### *Local anesthesia*

Applying to the external genitalia, a local anesthetic cream of a mixture of Lidocaine/Prilocaine (2.5 %/2.5 %) one-hour before USP. Thirty-minutes before a surgery, Valium 2.5–5 mg orally and Phenergan 12.5 mg suppository for light conscious sedation were administered. Local tissue infiltration of the operating field with Bupivacaine 0.5 % with epinephrine solution (Hospira, Inc., Lake Forest, IL USA) was sufficient to complete USP.

### Postoperative instruction

- Avoiding physical activities that significantly increased intra-abdominal pressure for 12 months
- Applying Dermoplast, pain relieving and antibacterial spray (Medtech Products, Inc. Irvington, NY, USA), to the external genitalia, every 4-h for postoperative two days and then as needed
- Taking acetaminophen two-tablets as needed for pain
- Using a strong chamomile solution for external genitalia hygiene.

### Steps in urethral stabilizing intervention

Each patient was in the dorsal lithotomy with lower extremities supported by Allen's stirrups. A number 12 Foley catheter was placed into the bladder cavity and drained to the gravity throughout the procedure and removed at the USP completion. Site-specific defects were reconstructed the same method by scarification of the defect edges within the USM and sutured edge-to-edge.

### Reconstruction of paravaginal defects

The paravaginal tissue interlocking with the perineal body, and the superior fascia of the levator ani muscle. It is imperative to reconstruct defects within all of these anatomical structures. In this study, access to the Retzius space for inspection was accomplished through an existing perineal membrane defect. An evaluation was caring out with a small flexible endoscope. Elevating the anterior suprapubic abdominal wall manually helps to visualize and to identify the defects.

In the current study, the paravaginal defect reconstructions were executed by transvaginal approach as described by Young et al. [24]. However, the current author made changes in Young et al. approach by a) scarified the edges of the defects; b) used 3-0 Vicryl suture on a taper CT-2 needle (Ethicon, Inc., USA). c) edge-to-edge approximation was

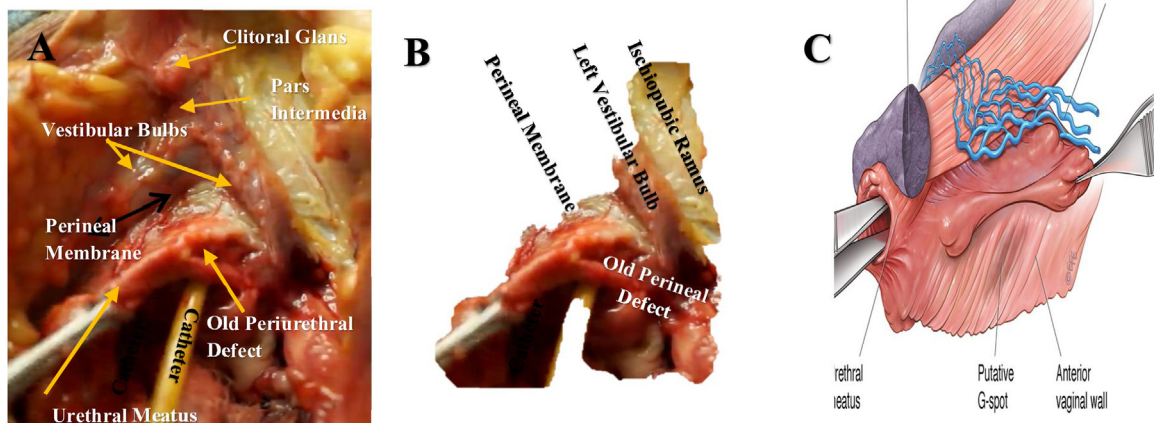
executed by avoiding wide placement of the suture. Such an approach in a suture placement minimizes folding and creating a tissue pleat. This author scarifies of the arcus tendineus fasciae pelvis, paravaginal fascia, superior fascia of the levator ani, and periurethral endopelvic fascia before the restorative process is initiated. The edge-to-edge defect is approximated by 3-0 Vicryl suture on the taper CT-2 needle (Ethicon, Inc., USA). These sutures are not placed widely around ATPF as Young et al. suggested. Vicryl suture were used instead of a Gore-Tex CV suture [24].

### Steps in the ventral perineal membrane reconstruction

- A transverse skin incision created with a number 15-size-surgical-scalpel-blade, 0.5 cm above the urethral meatus
- Getting access to the ventral perineal membrane, Fig. 1A and B.
- The endopelvic fascia is sharply dissected-off from natural fusion with the ventral perineal membrane
- Identifying the vaginal vestibular bulbs and advancing them upwards Fig. 1A,
- Exposing and identifying the perineal membrane site-specific defect, Figs. 1A, B, and 2 A.
- Surgical refreshing (scarification) of the perineal membrane defect(s) edges performed with a number 11-size-surgical-scalpel-blade, Fig. 2B, and approximating the edges with simple interrupted, 1-0 delayed absorbable sutures on a small tapered needle, Fig. 2C.
- The skin incision closed with a vertical mattress 4-0 delayed absorbable suture

### Steps in reconstructing ventral perineal membrane laxity

- The same method applied as presented in the above paragraph
- An elliptical excision of perineal membrane laxity made with a number 11- size-surgical-scalpel-blade, 1 cm below the attachment to the pelvic bone. Edges approximated with simple interrupted 1-0 delay absorbable sutures on a taper needle

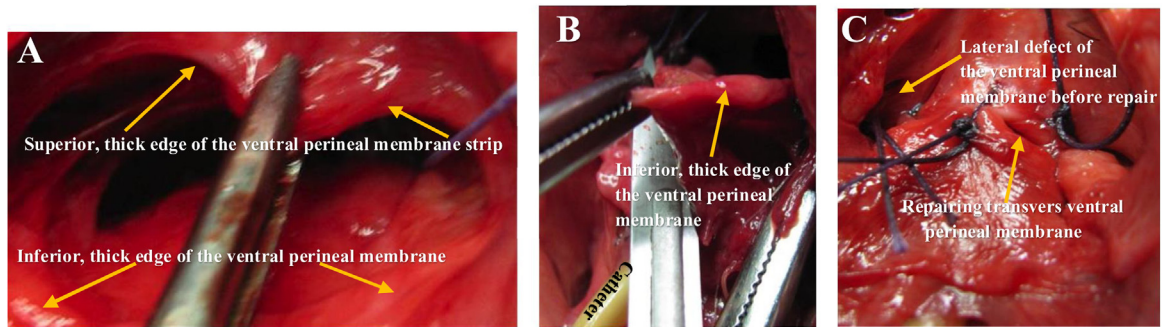


**Fig. 1.** Getting access to the ventral perineal membrane and identification of the urethral wall anatomical relationship with adjacent structures is depicted. Prof. Ostrzenski's archives used with permission.

**A.** The skin, endopelvic fascia, and bulbocavernosus muscles were removed to create access to the anterior urethral wall and adjacent anatomical structures. The left ischiopubic ramus was strip-off from the adipose tissue.

**B.** From Fig. 1A, the background tissue was removed electronically and left urethral wall indirect lateral fusion with the ventral perineal membrane, vestibular bulbs, and the ischiopubic ramus are shown.

**C.** Used with permission from the Journal of Sexual Medicine Editorial Office. The anatomical relationship between the urethra wall and the vestibular bulb (the bulb of the clitoris) is inaccurately presented and published in the scientific articles. [33] The vestibular bulb does not overly the urethral meatus, it runs alongside and parallels to the urethral meatus as it is documented in Fig. 1A.



**Fig. 2.** Identification of multiple defects within an anterior ventral perineal membrane. (For interpretation of the references to colour in this figure legend, the reader is referred to the web version of this article.)

**A.** The entire ventral perineal membrane attachment to the posterior is separated. The healed and thick edge of old ventral perineal membrane defect is depicted. The defective perineal membrane strip is fused with the posterior pubic arch and symphysis pubis, which will allow repairing the edge-to-edge reconstruction of the defect. The pre-fascial tissues of the superior and inferior surfaces of the ventral perineal membrane (light red color) were not removed.

**B.** Scarification of the inferior edge of the ventral perineal defect is in progress and executed with a no.11 surgical scalpel.

**C.** The transverse and lateral, ventral perineal membrane defects are repaired by applying single interrupted sutures. The lateral detachment of the ventral perineal membrane from the ischiopubic ramus is demonstrated before reconstruction.

- The skin incision closed with a vertical mattress using 4-0 delayed absorbable suture on a sharp needle.

#### Steps in distal para- and peri- urethral reconstruction

- A longitudinal skin incision made, 0.5 cm laterally from the urethral meatus and extended parallelly and downwards below the urethral carina
- Identifying the para-, peri-, and sub-urethral defects, Fig. 3A, and B
- Scarifying edges of the defects with a number 10-size-surgical-scalpel-blade and applying simple interrupted 0–1 delay absorbable sutures on a taper needle
- The skin closed with a vertical mattress, 4-0 delayed absorbable suture, Fig. 3C

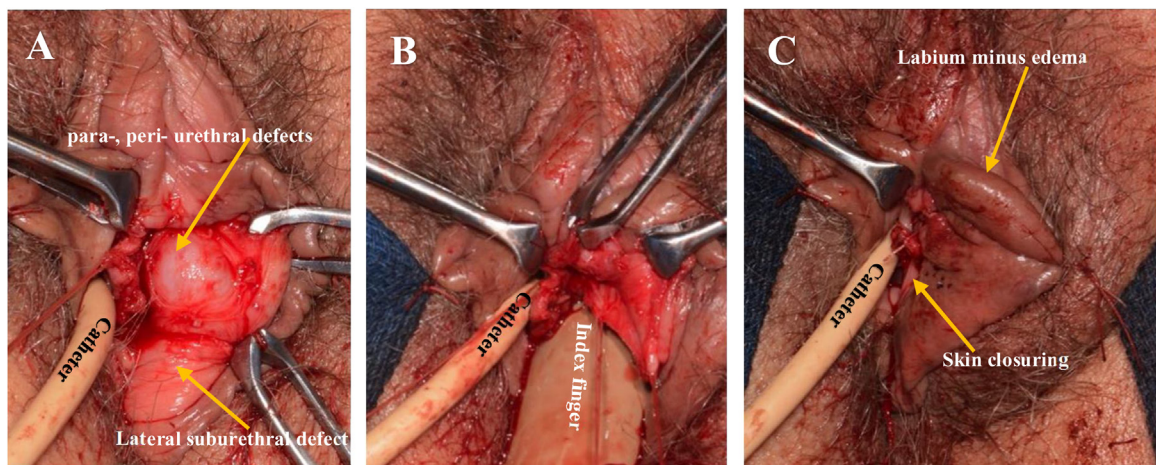
#### Steps in vaginourethral ligament reconstruction

- A transverse incision created on the anterior-distal vaginal wall with a number 10-size-surgical-scalpel-blade, 0.5–1.0 cm beneath the urethral meatus Fig. 4A,

- Dissecting the vaginal wall was continued in layers until the whitish in color vaginourethral ligaments identified Fig. 4A,
- Scarifying the edges of vaginourethral ligaments with a number 10-size- surgical-scalpel-blade and approximating the edges of defects with simple interrupted 1-0 delay absorbable sutures on a taper needle
- Vaginal wall closed with an interrupted vertical mattress, 4-0 delayed absorbable suture Fig. 4B,

#### Steps in suburethral reconstruction

- A transverse incision made on the anterior-distal vaginal wall, with a number 10-size-surgical-scalpel-blade, 0.5–1.0 cm below the urethral meatus and was continued to the vaginal surgical fascia (the vaginal adventitia) and the vaginourethral ligaments identified Fig. 4A,
- When a defect of the vaginourethral ligament identified Fig. 4A, the defect(s) of edges are scarified with a no.11-size-surgical-scalpel-blade and repaired with simple interrupted 2-0 delay absorbable sutures on a taper needle.
- Dissecting-off the vaginal surgical fascia from natural fusion with the vesical detrusor muscle Fig. 4A,

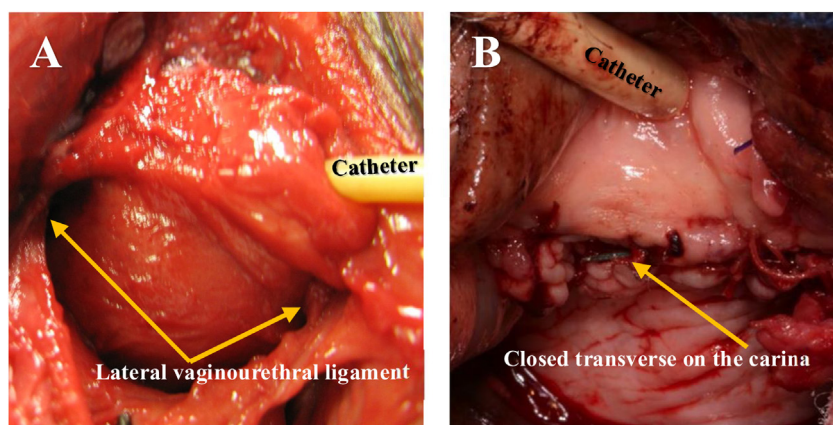


**Fig. 3.** Identification of para-, peri-, and sub-urethral defects.

**A.** A superficial skin incision was created and protruding para- and peri-urethral defects identified. The sub-urethral defect adhered to para-, peri-urethral defects.

**B.** Para- and par-urethral defects extending into the midsection of the distal paraurethral area to the depth of 2 cm and the surgeon's index finger demonstrates it.

**C.** A repaired para-, peri-urethral, and lateral sub-urethral defects.



**Fig. 4.** Identifying and reconstructing the lateral vaginourethral ligaments.

**A.** A transverse incision was made on the anterior-distal vaginal wall within the carina. The left and right vaginourethral ligament identified.

**B.** Reconstructions of para-urethral, peri-urethral, and suburethral defects have been completed. The transverse vaginal incision and paraurethral vertical incision were closed.

- Resecting the dorsal perineal membrane defect(s), and approximating the edge-to-edge of the defect with simple interrupted 1-0 delay absorbable sutures on a taper needle
- Resecting the defective full-thickness vaginal wall and closing with a continuous over-and-over 2-0 delay absorbable sutures on a taper needle

## Results

The current study verified that the pubourethral ligaments are the distal condensation of the arch tendinous fascia pelvis (ATFP) [26]. This finding demonstrates that ATFP has an additional connection (the paravaginal-paraurethral tissues) with the urethral wall.

The summary of the demographic characteristics of the subjects is presented in Tabl.1. Thirty-two patients completed the study (24 Caucasian, 4 Latino, 3 Black, and 1 Asian). All USP performed in the procedure room, and subjects discharged 2–3 hours after surgery. Out-of-town physicians who referred patients also conducted a

postoperative evaluation utilizing the study's protocol on seven-subjects (22 %). Two-women dropped-out from the study (6.2 %) due to geographic locations and no subject withdrew from the follow-up study because of adverse effect. A postoperative dynamic MRI examination documented that all identifiable preoperatively site-specific defects within the USM were surgically reconstructed. Immediately postoperatively, 95 % of patients reported regaining urinary continence. The follow-up at 60-month documented the subjective cure rate was in 92 %, and the objective cured rate in 88 %. At 60-month of monitoring, one patient (3.1 %) developed new urinary urge incontinence, which was not present at 36-month follow-up, Table 1. The perceived severity of uncomplicated SUI preoperatively changes to no symptoms postoperatively, Table 1. At the baseline, the Quality of Life was low and improved after USP, Table 1. There were no intraoperative complications. During the time of postoperative recovery, one patient (3.1 %) developed superficial wound separation, which healed spontaneously by secondary intention. Using the Clavien-Dindo classification determined the Grade I of surgical complications [25]. Postoperatively, no urinary retention develops in any

**Table 1**  
Treatment effect analysis.

Evaluation	Baseline	3-Month	6-Month	12-Month	24-Month	36-Month
PGI-I* (improvement)	N/A	25/32 (94.3) <sup>†</sup>	25/32 (94.3)	25/32 (94.3)	25/32 (91.7)	25/32 (91.7)
PGI-S** (severity)	32/32 (95.8) <sup>†</sup>	25/32 (4.1) <sup>†</sup>	25/32 (4.1)	25/32 (4.1)	25/32 (4.8)	25/32 (4.8)
Objective Cure	N/A	25/32 (91.1) <sup>†</sup>	25/32 (91.1)	25/32 (91.1)	25/32 (88)	25/32 (88)
Subjective Cure	N/A	25/32 (93.8) <sup>†</sup>	25/32 (93.8)	25/32 (93.8)	25/32 (91.7)	25/32 (91.7)
IIQ-7***						
Domain Score:						
1. <b>Physical activity</b> (Ability to do household chores; Physical recreation such as walking)	14.6±16.8	–	–	–	–	–14.2 ±17.8
2. <b>Travel</b> (Entertainment activities (movies, concerts, etc.; Ability to travel by car or bus more than 30 minutes from home)	26.8±17.5	–	–	–	–	–23.3 ±17.6
3. <b>Social/Relationship</b>	8.7±15.1	–	–	–	–	–7.5 ±15.5
4. <b>Emotional health</b> (nervousness, depression, embarrassment etc.; Feeling frustrated)?	46.1±35.1	–	–	–	–	–41.7 ±38.9

\* PGI-I: Patient Global of Improvement.

\*\* PGI-S: Patient Global Impression of Severity.

\*\*\* IIQ-7: The Incontinence Impact Questionnaire; Scoring.

<sup>†</sup> no./total no. (%).

patient, and no reoperation perform. Improvement of leakage episodes was reported by two patients a) reduced urine leakage episodes/24-hs from 9 at the base to 2 episodes/24-hs at the 60 months of follow-up; b) urine leakage episodes/24-hs from 6 at the base to 3 episodes at 60 months of follow-up.

## Discussion

The author would like to pay tribute to those surgeon-anatomists who investigated the urethral anatomy. Their work inspired me to conduct anatomical studies, which helped to improve our knowledge. Describing anatomical structures accurately is mandatory to guide a surgeon in reconstructive operations. The most difficult part of Ostrzenski's USP is to get access to the VPM. The vestibular bulbs must be surgically separated and advance upwards from VPM. In recent articles, the vestibular bulb anatomical description is inaccurately presented in the medical literature, Fig. 1C [33,34]. It will be beneficial for surgeons to familiarize themselves with both historical illustration of the vestibular bulbs Fig. 1C, and actual anatomical description with photographic documentation, Fig. 1A, and B.

## Main findings

The Urethral Stabilizing Mechanism natural assembly is in the form of a cross-like structure (anterior, posterior, and lateral):

- 1 An anterior retropubic compartment includes the anterior pubourethral ligaments (ATFP condensation), the paravaginal fascia, retropubic urethral fascia, the obturator internus muscle, the levator ani muscle, proximal urethra,
- 2 An anterior prepubic compartment houses: the posterior pubourethral ligaments (ATFP condensation), the pubovaginal ligaments, the ventral perineal membrane, the proximal part of the urethrovaginal sphincter muscle, the urethral compression muscle, the urethral part of the bulbocavernosus, and the urethral part ischiocavernosus muscle,
- 3 The lateral compartment is composed of the following anatomical structures: the para- and peri-urethral tissues, urethropelvic ligaments, midurethral attachments of the pubourethral ligaments (ATFP condensation), the pubovaginal ligaments, and the lateral aspect of the ventral perineal membrane,
- 4 The posterior compartment or suburethral compartment incorporates the anterior-distal part vaginal wall, the ventral endopelvic fascia, the dorsal perineal membrane, and the vaginourethral ligaments.

In the present study, the most common defects within the urethral stabilizing mechanism were the peri- and para-urethral defects Fig. 3A, B, vaginourethral ligament(s) defect Fig. 4A, ventral perineal membrane Fig. 2A, C. The most common combinations of the defects within the urethral stabilizing mechanism were the peri-, para-urethra defects Fig. 3A, B, and suburethral vaginourethral defects, Fig. 4A, and the ventral perineal membrane, Fig. 2A, C. Combinations of two or more defects were 91 %. The remaining 9 % was within the urethrovaginal sphincter muscle, the perineal membrane, and the perineal body.

The fibroconnective tissues suspend the urethra to the pelvic bones, ischiopubic ramus, and the ischial spine. Laterally, the urethra is suspended by the urethropelvic ligaments and supported by the dorsal perineal membrane, which attaches the urethra to the ischiopubic rami. Posteriorly, the dorsal perineal membrane supports the urethra and attaches it to the ischial tuberosity and the superficial transverse perineal muscle. Inferiorly, the anterior-distal vaginal wall and vaginourethral ligaments

support the posterior urethra. The ventral endopelvic fascia, peri-urethral and para-urethral tissue, dorsal perineal membrane, and the vaginourethral ligaments provide support for the suburethral area, which plays a role in uncomplicated SUI. Macura et al. in vivo MRI study established that having intact and symmetric periurethral ligaments reduced the odds of SUI by 87 % [27].

## Strengths and limitations

The electronic and manual searches of the literature documented that the USP is a new surgical intervention for uncomplicated SUI. The Strength of the current investigation rests in establishing:

- 1 The existence of the USM,
- 2 Occurrences of defects within USM,
- 3 The new surgical treatment (USP) for uncomplicated SUI,
- 4 The prosper to eliminate using surgical slings, meshes or permanent sutures,
- 5 No severe complication USP observed.

The limitations of this investigation were small sample size, no control group, and the type of study (a prospective case series study), which precludes to determine the safety and the effectiveness of USP. Additionally, the subjects with elevated BMI were not well-represented due to the study designed as consecutive case selections.

## Interpretation

In urinary continent women, isolated urethral hypermobility is in the range 13 % [28]. The current study documented urethral hypermobility, urine leakage, and residual urine more than 150 mL were identified in each subject of this study.

There is no similarity between the USP and Kelly's procedure. In Kelly's procedures, a surgeon places a buttress suture at the bladder neck to plicate the vaginal tissue [29]. In the USP, the site-specific defects of a suburethral region are reconstructed stratum-by-stratum in order to reinstate the integrity of the USM.

There is no similarity between the USP and the retropubic Marshall-Marchetti-Krantz (MMK) procedure, in which the urethra is elevated by inserting the sutures, one on each side, at the bladder neck level and attaching these sutures to the periosteum of the medial pubic bones [30]. In the USP, the urethra is not elevated, no periosteum is used for urethral anchoring, no sutures placed on the urethral wall. Unlike MMK, the USP surgical concept is to reconstruct all identifiable site-specific defects within the USM.

The suburethral slings provide the objective and subjective long-term cure rates in 68 % and 87 % respectively [31]. In 1990s, the midurethral sling was introduced for the treatment of SUI with overall 84 % cure rate and was most commonly used surgical intervention for the therapy of SUI. The midurethral sling procedure elevates the urethra and supports the bladder neck without repositioning it [40]. In the view of low but severe complications, the NHS in UK suspended the use of any type of slings for the SUI therapy [9]. The US FDA stopped using surgical meshes for the anterior vaginal wall reconstruction [10]. Contrary to a sling or mesh operation, Ostrzenski's USP restores a natural support and suspension of the urethra with the native tissue. Unlike midurethral sling, USP does not artificially elevate the urethra, but restores a natural supporting-suspensory anatomical mechanism. The present study established that the objective and subjective cure rates are 88 % and 92 % respectively.

Reviewing the medical literature failed to identify any scientific-clinical report about a functional correlation between

repaired anatomical structures within USM and their contribution to urinary continence in women. The urethral apparatus of USM anatomical complex and its contribution to urinary continence in women has never been studied and needs to be investigated to answer such a question. Functional interpretations of fragments of the urethral suspension and support structures can be identified in the medical literature; however, the speculative nature of this information does not allow interpreting adequately urethral suspension-support due to the anatomical fragments being incorporated into the historical study.

Clinical and basic science researchers suggested that complex anatomical structures interact between themselves to maintain urinary continence in women [11,12,16]. However, this anatomical complex has never been determined as a whole. The current author advanced a hypothesis that site-specific anatomical defects within this whole complex can compromise the function of urinary continence in women. When the anatomical components do not act in concert, dysfunction of urinary continence can occur, and consequently, it may lead to stress urinary incontinence. Recently, Ostrzenski identified site-specific defects arising within the USM [16]. It is the very first time that the research attention was turned to the defects in the regions, which were not previously considered as a potential cause for SUI, such as VPM defect(s) or the lateral vaginourethral ligaments, lateral vaginal wall defects, or peri-, and para-urethral defects. The critical aspect of the current study rests in documentations that reconstructions of the defect(s) within USM are possible, and it can be accomplished by utilizing the native tissues. Discovering the anatomy of the urethral stabilizing mechanism and occurrences site-specific defects within this complex was a giant step in understanding the SUI etiology [16]. Repairing defects within the USM yielded the high cure rate (88 % objective and 92 % subjective cure rate) supporting the notion that anatomical structures work best together when the site-specific defects are repaired.

#### *Integral Theory (IT) of Female Urinary Incontinence*

In 1990, Petros and Ulmsten created, by reviewing medical literature, the Integral Theory of Female Urinary Incontinence for *urge* and *stress* urinary incontinence. The authors perceived the vaginal role in a) conveying muscles activities at the bladder neck level, b) participating in the urethral closure mechanism as the hammock (the anterior-distal vagina), and c) preventing the bladder neck and proximal urethra to stretch.

#### *Comparison between IT and Ostrzenski's Etiology (OE) can be summarized*

- **IT** was created for two different medical entities of urinary incontinence in women, urge incontinence and SUI. One package of potential causes for both entities was offered. **OE** is established for SUI only.
- **IT** is based on the multifactorial causes; however, not all causes are applicable either to SUI or urge incontinence (connective tissue disorders, muscle dysfunctions, peripheral nerve damage; iatrogenic causes; dysfunction of the urethral closure mechanisms; vaginal hammock defect; loose pubourethral ligaments; loose uterosacral ligaments; loose vaginal wall at the bladder neck). Unlike the **IT**, the **OE** uses one cause only for SUI (anatomical defects within the USM)
- **IT** multifactorial causes require multiple treatments. The **OE** provides one method of therapy (USP)
- **IT** cannot assist a surgeon in selecting an appropriate surgical intervention(s). **OE** helps a surgeon in choosing a surgical intervention (USP)
- **IT** does not discriminate between urethral hypermobility (suburethral support defects) and urethral hypomobility (the

urethral lifting support mechanism). **OE** discriminates hyper- and hypomobility of the urethra.

#### *Hammock hypothesis (HH)*

In 1994, Delancey presented the **HH**, which was based on gross anatomy research conducted on embalmed and fresh female cadavers [32]. In the same article, DeLancey declared that a cadaveric gross anatomical study could not be used for determining the functional anatomy [32]. Therefore, the **HH** can only be interpreted as the theoretical supposition and not as a functional anatomy hypothesis.

DeLancey accepts Enhörning's hypothesis of the intraabdominal pressure transmission to the retropubic part of the proximal urethra at the level of the vesical neck and DeLancey provides a speculative explanation that the urethra descends under the increased abdominal pressure. This mechanism places the hammock structures on a tension that closes the urethral lumen [32,34]. It is not entirely clear that the pressure transmission is the only factor in urethral descent since intraoperatively, Ingelman-Sundberg describes the existence of the vaginourethral ligaments attach to the urethral wall and then traverse up to the pubic arch. Additionally, the author speculatively postulates that these ligaments are responsible for the clitoral-urethral complex to descend.<sup>33</sup> Whether the intraabdominal pressure transmission or the lateral vaginourethral ligaments or both are participating in urethral descent, the new study should be conducted to provide a definitive understanding.

#### *Comparison between HH and OE can be recapped*

- **HH** was created for SUI, and **OE** was also established for SUI
- **HH** is based on one cause for SUI, the anatomical defects within the hammock anatomical structures (the endopelvic fascia, vaginal wall, arcus tendineus fasciae pelvis, and the levator ani muscle). **OE** is also based on one cause for SUI, anatomical defects within the USM
- **HH** suggests reconstructing the anatomical defects within hammock structures for a SUI cure. **OE** was based on the present study results of defect reconstructions within the USM
- **HH** cannot assist a surgeon in selecting an appropriate surgical intervention(s) for SUI since hammock structures are only particular fragments of anatomy, which support and suspend the urethra. **OE** helps a surgeon to choose a surgical intervention for SUI
- **HH** did not offer a specific surgical intervention to repair defects within hammock structures. **OE** provides an accurate description of reconstructions for defective anatomical structure reconstructions within the USM in different anatomical regions.
- **HH** suggests reconstructing suburethral vaginal wall, which is one of the components of the hammock. **EO** recommends reconstructing the lateral vaginourethral ligaments for SUI. Very long-term clinical observations provide enough information that isolated anterior vaginal wall prolapse (cystocele) can exist without urinary incontinence. This fact eliminates the vaginal wall as a solo component in maintaining continence. Kelly's procedure placates the anterior-distal vaginal tissue under the bladder neck area. This operation did not withstand the test of time [29]. Therefore, the vaginal wall itself does not play an essential role in urinary continence, but the lateral vaginourethral ligaments play a role in SUI therapy as it was documented in the present study. Ostrzenski established that the suburethral compartment incorporates the endopelvic fascia, dorsal perineal membrane, anterior-distal vaginal wall as well as the vaginourethral ligaments [16]. To restore urinary continence, all structural

defects within the suburethral compartment must be reconstructed when site-specific defect(s) is identified.

The hammock concept is difficult to comprehend from the mechanical point of view. A hammock-like structure must have a pivot located laterally and the anatomy of this area indicates that bilaterally vaginourethral ligaments are located in the lateral corners of the anterior-distal vagina [16,33]. These ligaments connect the distal urethra, in the vicinity of the urethral meatus, with the lateral vagina [16,33]. Such a location of these ligaments most likely will bring the lateral vagina medially and not stretching the vagina laterally as **HH** suggests. This aspect of **HH** will require a new functional anatomy investigation.

#### Urethral hanging theory (UHT) and OE

In 2016, Bergström published the **UHT** for SUI in women. The theory was based on urodynamic results and published in the Letter-to-Editor [39]. Bergström provided interpretation for the urethral funneling mechanism, quote: “... the proximal urethra is forced downward in relation to the bladder neck until it is stopped by hanging on the bladder neck and is thereby funneled by pulling forces” [38]. UHT included the defective vaginal wall supporting mechanism and a defect(s) within the posterior pubourethral ligaments. Such an arrangement leads to urethral funneling and SUI. Bergström suggested that urethral hanging is the pathophysiology of SUI. This new concept must be verified in the gross and functional anatomy study, before a comparison can be done.

Ostrzenski's previous gross anatomical study on fresh cadavers established that neither the pubovesical ligament (the lateral or medial pubovesical ligament in women) nor transverse pre-cervical arc of Gilvernet is a part of the urethral stabilizing mechanism. Both of these structures support the bladder neck [11,41,42]. The transverse pre-cervical arc of Gilvernet is the thick extension of the pubovesical ligament condensation and inserts to the anterior wall of the bladder and restrains a posterior displacement of the anterior bladder wall. Additionally, this structure rotates downwards to close off the bladder neck during stress and precludes the anterior bladder wall from collapsing during micturition [41]. The Gilvernet's transverse pre-cervical arc laid the foundation for the urethral closure mechanism concept [11,41,42].

The pubococcygeus muscle is divided into three branches: the pubovaginalis, puborectalis, and the puboperinealis muscle. The pubococcygeus medial fibers (the pubovaginalis muscle) fuses with the lateral-midsection of the vaginal wall and with ATPF, which suspends the lateral vagina to the posterior pubic bones and the ischial spine. Separation of this connection can cause SUI. However, whether the paravaginal defect can be solo responsible for SUI in women is difficult to judge because the paravaginal tissue interlocking with the perineal body, and the levator ani muscle and their anatomical defects can cause SUI. Consequently, without an additional study, the question remains unanswered. The surgical interventions for paravaginal reconstruction have been described a) the abdominal approach for SUI was presented by Richardson [36]; b) a laparoscopic approach was developed by Ostrzenski [37]; c) transvaginal method was described by Young et al. [24,35].

#### Conclusions

In this study group, the urethral stabilization procedure yields high degree of subjective and objective cure rates without severe complications, with a short-learning-curve, is well-tolerated by subjects. USP is a reproducible method for surgical therapy of uncomplicated SUI in women with a significant potential for clinical practice implementation and scientific research. The

defects within the urethral stabilizing are the etiology for SUI in women.

#### Contribution to authorship

The author solo work.

#### Details of ethics approval

The Local Ethics Committee approved the study protocol (AKBE 146/12).

#### Funding

None.

#### Declaration of Competing Interest

None.

#### Acknowledgments

The author owns special thanks to Prof. Dr. Pawel Krajewski, chairman of the Department of Forensic Medicine, Warsaw Medical University, Poland, for selecting corps to conduct a rehearsal of urethral stabilization procedure.

#### References

- [1] Leach GE, Dmochowski RR, Appell RA, Blaivas JG, Hadley HR, Luber KM, et al. Female Stress Urinary Incontinence Clinical Guidelines Panel summary report on surgical management of female stress urinary incontinence. *Am Urol Assoc J Urol* 1997;158(3 Pt 1):875–80.
- [2] Rovner ES, Ginsberg DA, Raz S. American Urogynecologic Society's Guidelines Development Committee Panel summary report on surgical management of female stress urinary incontinence. *J Urol* 1998;159(5):1646–7.
- [3] Lucas MG, Bosch RJ, Burkhard FC, Cruz F, Madden TB, Nambiar AK, et al. European Association of Urology. EAU guidelines on surgical treatment of urinary incontinence. *Eur Urol* 2012;62(6):1118–29.
- [4] The American Urogynecologic Society (AUGS) and the Society for Urodynamics, Female Pelvic Medicine and Urogenital Reconstruction (SUFU). Mesh midurethral slings for stress urinary incontinence. *Urol Clin North Am* 2012;41(3):353–62.
- [5] Blaivas JG, Purohit RS, Benedon MS, Mekel G, Stern M, Billah M, et al. Safety considerations for synthetic sling surgery. *Nat Rev Urol* 2015;12(9):481–509.
- [6] Hansen BL, Dunn GE, Norton P. Long-term follow-up of treatment for synthetic mesh complications. *Female Pelvic Med Reconstr Surg* 2014;20(3):126–30.
- [7] Daneshgari F, Kong W, Swartz M. Complications of mid urethral slings: important outcomes for future clinical trials. *J Urol* 2014;180(5):1890–7.
- [8] Amundsen CL, Flynn BJ, Webster GD. Urethral erosion after synthetic and nonsynthetic pubovaginal slings: differences in management and continence outcome. *J Urol* 2003;170(1):134–7.
- [9] The National Health Service (NHS). “Extension of pause to the use of vaginal mesh” and the Royal College of Obstetricians & Gynecologist (RCOG). “mesh safety alert”. 2018 <https://www.rcog.org.uk/en/guidelines-research-services/.../mesh-safety-alert/> (Accessed 16 April 2019).
- [10] The U.S. Federal Drugs Administration (FDA). <https://www.fda.gov/medical-devices/.../implantsandprosthetics/urogynsurgicalmesh/>, 2019 (Accessed 16 April 2019).
- [11] Petros PE, Ulmsten UI. An integral theory of female urinary incontinence. Experimental and clinical considerations. *Acta Obstet Gynecol Scand Suppl* 1990;153:7–31.
- [12] DeLancey JOL. Fascia and muscular abnormalities in women with urethral hypermobility and anterior vaginal wall prolapse. *Am J Obst Gynecol* 2002;187:93–8.
- [13] Zachrin RF. The anatomic support of the female urethra. *Obstet Gynecol* 1968;32(6):754–9.
- [14] Wilson PD, Dixon JS, Brawn ADG, Gosling JA. Posterior pubo-urethral ligaments in normal and genuine stress incontinent women. *J Urol* 1983;130:802–5.
- [15] Petros PE. The pubourethral ligaments—an anatomical and histological study in the live patient. *Int Urogynecol J Pelvic Floor Dysfunct* 1998;9(3):154–7.
- [16] Ostrzenski A. New site-specific anatomical defects discovered within the female urogenital tract. *Eur J Obstet Gynecol Reprod Biol* 2019;237(June):164–9.
- [17] Committee Opinion No. 603. The American College of Obstetricians and Gynecologists. *Obstet Gynecol* 2014;123:1403–7.

- [18] Crystle CD, Charme LS, Copeland WE. Q-tip test in stress urinary incontinence. *Obstet Gynecol* 1971;38(2):313–5.
- [19] Stoker J, Rociu E, Bosch JL, Messelink EJ, van der Hulst VP, Groenendijk AG, et al. High-resolution endovaginal MR imaging in stress urinary incontinence. *Eur Radiol* 2003;13:2031–7.
- [20] Tasali N, Cubuk R, Sinanoğlu O, Sahin K, Saydam B. MRI in stress urinary incontinence: endovaginal MRI with an intracavitary coil and dynamic pelvic MRI. *Urol J* 2012;9:397–404.
- [21] Sandvik H, Hunskaar S, Seim A, Hermstad R, Vanvik A, Bratt H. Validation of a severity index in female urinary incontinence and its implementation in an epidemiological survey. *J Epidemiol Community Health* 1993;47(6):497–9.
- [22] Yalcin I, Bmp RC. Validation of two global impression questionnaires for incontinence. *Am J Obstet Gynecol* 2003;189:98–101.
- [23] Uebersax JS, Wyman JF, Shumaker SA, McClish DK, Fantl JA. The incontinence impact questionnaire and the urogenital distress inventory. *Neurourol Urodyn* 1995;14:131–9.
- [24] Young SB, Daman JJ, Bony LG. Vaginal paravaginal repair: one-year outcomes. *Am J Obstet Gynecol* 2001;185(6):1360–6.
- [25] Dindo D, Demartines N, Clavien PA. Classification of surgical complications: a new proposal with evaluation in a cohort of 6336 patients and results of a survey. *Ann Surg* 2004;240(2):205–13.
- [26] Pit MJ, De Ruiter MC, Lycklama A, Nijeholt AA, Marani E, Zwartendijk J. Anatomy of the arcus tendineus fasciae pelvis in females. *Clin Anat* 2003;16(2):131–7.
- [27] Macura KJ, Thompson RE, Bluemke DA, Genadry R. Magnetic resonance imaging in the assessment of stress urinary incontinence in women: Parameters differentiating urethral hypermobility and intrinsic sphincter deficiency. *World J Radiol* 2015;7(11):394–404.
- [28] Nager CW, Brubaker L, Litman HJ, Zyczynski HM, Varner RE, Amundsen C, et al. A randomized trial of urodynamic testing before stress-incontinence surgery. *N Engl J Med* 2012;366(21):1987–97.
- [29] Kelly HA. Incontinence of urine in women. *Urol Cutaneous Rev* 1913;6:291–3.
- [30] Marshall VF, Marchetti AA, Krantz KE. The correction of stress incontinence by a simple vesicourethral suspension. *Surg Gynecol Obstet* 1949;88(4):509–18.
- [31] Latthe PM, Singh P, Foon R, Tooze-Hobson P. Two routes of transobturator tape procedures in stress urinary incontinence: a meta-analysis with the direct and indirect comparison of randomized trials. *BJU Int* 2010;106(1):68–76.
- [32] DeLancey JO. Structural support of the urethra as it relates to stress urinary incontinence: the hammock hypothesis. *Am J Obstet Gynecol* 1994;170(June (6)):1713–20.
- [33] Ingelman-Sundberg A. The anterior vaginal wall as an organ for transmission of active forces to the urethra and the clitoris. *Int Urogynecol J* 1997;8:50–1.
- [34] Enhörning G. Simultaneous recording of intravesical and intra-urethral pressure. A study on urethral closure in normal and stress incontinent women. *Acta Chir Scand Suppl* 1961;(Suppl. 276):1–68.
- [35] White GR. A radical cure by suturing lateral sulci of vagina to white line of pelvic fascia. *JAMA* 1909;21:1707–11.
- [36] Richardson AC, Edmonds PB, Williams NL. Treatment of stress urinary incontinence due to paravaginal fascial defect. *Obstet Gynecol* 1981;57(March (3)):357–62.
- [37] Ostrzenski A. Genuine stress urinary incontinence in women. New laparoscopic paravaginal reconstruction. *J Reprod Med* 1998;43(June (6)):477–82.
- [38] Young SB, Daman JJ, Bony LG. Vaginal paravaginal repair: one-year outcomes. *Am J Obstet Gynecol* 2001;185(December (6)):1360–6.
- [39] Bergström Bo S. Urethral hanging theory. *Neurourol Urodyn* 2016(April (April) DOI 10.1002/nau.
- [40] Ulmsten U, Henriksson L, Johnson P, Varhos G. An ambulatory surgical procedure under local anesthesia for treatment of female urinary incontinence. *Int Urogynecol J Pelvic Floor Dysfunct* 1996;7(2):81–5.
- [41] Dyrkorn OA, Kulseng-Hanssen S, Sandvik L. TVT compared with TVT-O and TOT: results from the Norwegian National Incontinence Registry. *Int Urogynecol J* 2010;21(November(11)):1321–6.
- [42] Petros P. The female pelvic floor function, dysfunction and management according to the integral theory. second edition Germany: Springer Medizin Verlag Heidelberg; 2007. p. 18.