

New retroperitoneal culdoplasty and colpopexy at the time of laparoscopic total abdominal hysterectomy (L-TAH)

ADAM OSTRZENSKI

From the Division of Operative Gynecology, Endoscopy and Laser Surgery, Department of Obstetrics and Gynecology, Howard University College of Medicine and Howard University Hospital, Washington DC, USA

Acta Obstet Gynecol Scand 1998; 77: 1017–1021. © Acta Obstet Gynecol Scand 1998

Background. After a laparoscopic total abdominal hysterectomy, the safety of the translaparoscopic, prophylactic, retroperitoneal pouch of a Douglas reconstruction and vaginal vault suspension was evaluated.

Methods. This operation was adapted from the laparotomy approach and has been investigated from July, 1992, to July, 1996. Modest modifications have been introduced to meet laparoscopic technology requirements. Observational clinical trials have been conducted on 112 women. The surgery was performed through laparoscopy by suturing and tying method, with no vaginal approach.

Results. This clinical trial showed positive results for the operation, with no complications observed in this group of patients. After the operation, there were no symptoms or signs of a dysfunctional vagina, or pelvic relaxation.

Conclusion. This preventive operation is safe and it restores the pelvic topography, functional anatomy, and it prevents post-hysterectomy vaginal dysfunction disorders.

Key words: colpopexy; culdoplasty; hysterectomy; laparoscopic surgery; vaginal suspension

Submitted 30 May, 1997

Accepted 4 March, 1998

A review of the existing world body of literature through Medline and AGOGNET computerized databases was conducted on the following subjects: enterocele formation, vaginal cuff descent, vaginal prolapse, and dyspareunia following laparoscopic hysterectomy. The review of literature failed to identify the incidence of these clinical long-term adverse events.

Since Semm (1) performed the first vaginal hysterectomy with laparoscopic assistance in 1984 and published his findings in 1993, several clinical series analyses have been presented on laparoscopically assisted vaginal hysterectomy (2–

7), on laparoscopic hysterectomy with ligation of the uterine arteries translaparoscopically (8–10), and on laparoscopic supracervical amputation of the uterine corpus with excision of the endocervical mucosa (11–12) or with retention of the endocervical mucosa (13, 14). These laparoscopic hysterectomy techniques (1–14) did not describe a method in which hysterectomy and vaginal vault suspension or vaginal closure were executed only through laparoscopy without any transvaginal surgery from below. Contrary to these technical approaches of laparoscopic hysterectomy, in 1992 (15), 1993 (16, 17), and 1996 (18), Ostrzenski published a laparoscopic hysterectomy technique executed completely via laparoscopy by suturing technique. The classic laparotomy involving a total abdominal hysterectomy technique

Abbreviations:

US: uterosacral ligaments; CL: cardinal ligament; Vg: vaginal lumen; L-TAH: laparoscopic total abdominal hysterectomy.

was adapted by Ostrzenski, and the laparoscopic approach and laparoscopic technology were new elements in his L-TAH. In order to distinguish Ostrzenski's laparoscopic hysterectomy technique from the total laparoscopic hysterectomy technique described by Garry and Riech in 1993 (19), a new nomenclature of laparoscopic total abdominal hysterectomy (L-TAH) was introduced and published in the peer review journal *International Journal of Gynaecology and Obstetrics* in 1996 (18).

In 1982, Ostrzenski introduced retroperitoneal, prophylactic posterior culdoplasty and vaginal vault suspension during a classic abdominal hysterectomy, and published his ten year observations in 1995 (20) and in 1996 (21). Encouraged by the outcome of the operation and patient satisfaction, the author adopted this technique to be utilized at the time of laparoscopic total abdominal hysterectomy by using a suturing method with no transvaginal approach.

The purpose of this prospective, coherent, descriptive, observational clinical study was to evaluate the safety of a new technique of retroperitoneal posterior culdoplasty and vaginal cuff suspension during a laparoscopic total abdominal hysterectomy.

Materials and methods

Total laparoscopic abdominal hysterectomy with prophylactic posterior culdoplasty and vaginal cuff suspension was performed on 112 patients. Surgeries were performed from July, 1992, to July, 1996, at either the Institute of Video Endoscopy and Laser of Washington or at Howard University Hospital, Washington, DC, USA. All operations were performed by the author, with residents serving as first assistants in some cases. The operation was accomplished with a translaparoscopic suturing and tying method that used an extracorporeal sliding knot enhanced with a two-turn flat square intracorporeal knot.

Pre-operatively, the following indications for laparoscopic total abdominal hysterectomy were established: symptomatic leiomyomata uteri (59 cases, 53%); dysfunctional uterine bleeding refractory to conservative medical management (27 cases, 24%); adenomyosis (11 cases, 10%); chronic pelvic pain unresponsive to conservative therapy (eight cases, 7%); endometrial atypical complex hyperplasia (five cases, 4%); and micro-invasive cervical carcinoma (two cases, 2%).

Clinical criteria were implemented to exclude subjects from this study: gynecological oncology patients when the invasive stage of the malignant process was diagnosed pre-operatively; uterine en-

largement corresponding to 14 weeks of gestational size; or clinical condition qualifying for transvaginal surgical approach.

Patients received full information about the type of vaginal vault suspension and posterior culdoplasty currently practiced in our institution, and the difference between the laparotomy and laparoscopy approaches. Patients were free to choose between these two methods. Written informed consent was obtained from each patient.

Surgical technique

The operation was performed under general anesthesia, with the patient in the modified dorsolithotomy and Trendelenburg's position. Upon completing the laparoscopic total abdominal hysterectomy (L-TAH), utilizing the technique previously described by this author (15–18), the retroperitoneal-rectovaginal space, the anterior rectal and the vaginouterine fascia, and the deep layer of the uterosacral ligament stumps were recognized. In 1921, Okabayashi (22) introduced the clinical concept that there were two layers: superficial (peritoneal), and deep (connective tissue) within the uterosacral ligament.

The right deep layer of the uterosacral ligament was pierced with a no. 0-PDS (Polydioxanone) Endoknot absorbable suture. The suture was brought through the anterior rectal fascia and entered the left deep layer of the uterosacral ligament on the opposite side. The same suture was then passed through the posterior vaginouterine fascia and emerged from the right uterosacral ligament (Fig. 1).

The lateral-posterior aspect of the vaginal wall was suspended by bilaterally suturing the stumps of the cardinal ligaments (Fig. 1). The vesicocervical fascia was sutured to the anterior vaginal wall. Caution was exercised so that the needle and suture avoided the rectal and vaginal mucosa.

The vaginal cuff was closed by approximating the anterior edge to the posterior edge of the vaginal wall with a single type laparoscopic no. 0-PDS Endoknot suture (Fig. 1). The final step was to bring the superficial layer of the uterosacral ligament over the deep layer of the uterosacral ligament bilaterally.

When adnexa were left behind in the surgery, a reperitonealization was performed with a no.0000-PDS suture to prevent retroperitoneal spontaneous placement of the structures.

In order to complete the operation the following laparoscopic instruments and suture material were used:

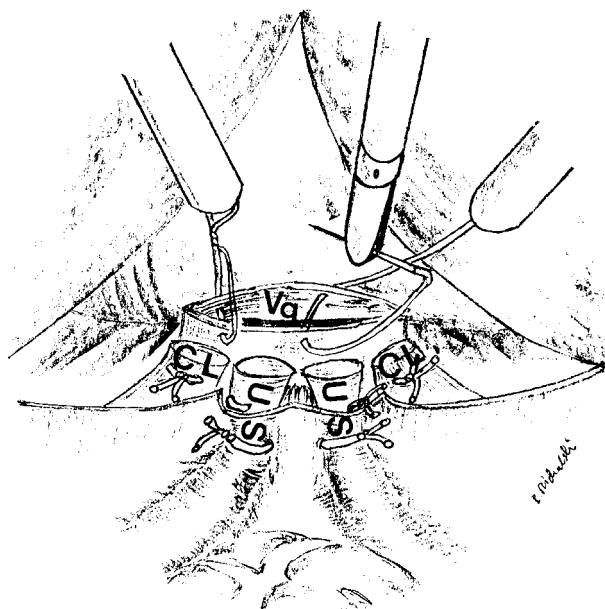


Fig. 1. The retroperitoneal, deep layer of the uterosacral ligaments (US) were incorporated into posterior culdoplasty and posterior aspect of vaginal suspension. Bilaterally, the cardinal ligament (CL) were approximated to the lateral-posterior surface of the vagina. Anteriorly, the vagina was suspended to the pubovesicocervical fascia. Process of the vaginal lumen (Vg) closure from anterior to posterior edge is depicted.

- 1) two laparoscopic tissue graspers (Karol Storz, Germany),
- 2) one tissue and one suture 5 mm laparoscopic scissors (Karol Storz, Germany), and a 5 mm needle holder (Karol Storz, Germany),
- 3) a no. O-PDS Endoknot, and straight needle (Ethicon, USA).

To determine a safety of these new operations, the following clinical parameters were evaluated:

1. Operating time, measured by passing the extirpated uterus through the vaginal pool until the completion of posterior culdoplasty, vaginal vault suspension, vaginal lumen closure, and re-peritonealization.
2. Complications, including intra-operative, immediate post-operative, and late postoperative. An anesthesiology resident was assigned to register any complications (surgical and/or anesthesiologic) intra-operatively and at the early stage of recovery. Immediate and late post-operative complications were documented herein by this author.
3. Long term post-operative follow-up for ruling in or ruling out enterocele formation, vaginal cuff descent, vaginal prolapse, and dyspareunia. The long term follow-up was started 6 months after the operation, and was conducted on a yearly basis thereafter.

Results

The age of the patients ranged from 24–72 years, with an average age of 47 years. Parity ranged from 1 to 5, with an average of 2.4. Weight ranged from 123–267 lbs., with an average weight of 170 lbs.

Seventeen out of 112 patients (15.18%) did not participate regularly in post-operative follow-up, and those subjects were excluded from final analysis. Therefore, 95 patients were able to complete the study. Thirty-two out of 97 patients (33.68%) were evaluated for 4 years, 29 subjects (30.53%) for 3 years, 23 women (24.21%) for 2 years, 11 women (11.58%) for one year.

The surgical time of posterior culdoplasty, vaginal vault suspension, vaginal closure ranged from 27–53 minutes, with an average of 42 minutes. Neither anesthesia related nor intraoperative complications were encountered.

During the immediate post-operative period, one patient required 2 units of blood transfusion (pre-operative hemoglobin 10.1 g/dl and immediate post-operative hemoglobin level 8.7 g/dl; patient became symptomatic).

Among this group of patients, there were no cases of enterocele formation, descent of the vaginal cuff, vaginal prolapse, or dyspareunia.

Discussion

In my opinion that was published in a peer review journal (23), enterocele is a misnomer for true hernia of the cul-de-sac of Douglas. The hernia sac contains a portion or portions of the intestine, but the intestine itself is not a diseased organ. The endopelvic fascia is weakened and/or attenuated. There is no other hernia in the human body that is named according to the organs trapped inside the hernia pocket. In all abdominal hernias, a peritoneal sac is present which distinguishes hernias from, for instance, a cystocele or rectocele. These are correctly termed ‘-cele’ and cystocele or rectocele defects will require a different surgical approach than a true hernia repair with a peritoneal sac surrounding it. Wilensky and Kaufman (24) described three forms of enterocele: anterior, posterior, and lateral. This publication expresses only a prophylactic step to prevent a posterior enterocele formation. Nichols (25) classified posterior enterocele, based upon differences in etiologic factors, into four categories: congenital, pulsion, traction, and iatrogenic. Among these four basic types of enterocele, only the iatrogenic type will be prevented by the operation described here.

In this report, the classification of pelvic support disorders has been adapted from Shull et al. (26),

Table I. Differences between the classic vaginal vault suspension/culdoplasty and laparoscopic new techniques

Surgical anatomical structures	Classic technique	New technique	Comment
	Extraperitoneal	Retroperitoneal	Fundamental differences in surgical concept
The round ligament	Utilized for suspension	Not utilized for suspension	<ol style="list-style-type: none"> 1. Use of the round ligament changes the natural vaginal angle, and elevates the vaginal cuff, exposing the rectovaginal space to fluctuating intra-abdominal pressure (which can cause a predisposition to enterocele formation). 2. The round ligament is neither a neighboring structure to the vagina, nor a structurally strong connective tissue.
The superficial layer of the uterosacral ligament	Utilized for suspension	Not utilized for suspension	In 1921, Okabayashi (22) introduced the clinical concept that there were two functional layers of the uterosacral ligament: superficial (used in Ostrzenski's technique for remodeling the cul-de-sac peritoneum), and deep, retroperitoneal strong connective tissue.
The deep layer of the uterosacral ligament	Not utilized for suspension	Utilized for suspension	<ol style="list-style-type: none"> 1. In Ostrzenski's technique, the stronger, retroperitoneal part of the ligament is used after hysterectomy to reconstruct the hollow in the rectovaginal space and posterior cul-de-sac. 2. In this sequence of the operation, it builds a strong foundation on which the posterior vaginal wall is suspended and stabilized in order to receive the anterior vaginal wall. Both the newly reconstructed rectovaginal space and the cul-de-sac become the brace for vaginal alignment parallel to the levator plate and rectum.
The cardinal ligament	Not utilized for suspension	Utilized for suspension	<ol style="list-style-type: none"> 1. This is one of the strongest pelvic ligaments. The latero-posterior vaginal apex is suspended to it in the new technique, in a manner similar to natural attachment. 2. The integrity of the gross and functional anatomy, as well as of the vaginal topography in the pelvis, is restored after hysterectomy.
The rectal fascia	Not utilized for suspension	Utilized for suspension	The strong retroperitoneal pararectal tissue is an ideal anatomical structure for durable reconstruction.
The vagino-uterine fascia	Not utilized for suspension	Utilized for suspension	The strong retroperitoneal paravaginal tissue is an ideal anatomical structure for durable rectovaginal space reconstruction.

which is based upon: 1) organ(s) involved, 2) organ dysfunction, 3) site of descents or prolapse, 4) grade of severity. However, this aspect of the discussion is beyond the scope of the objectives of this article and readers may find details on this subject in Shull et al.'s (26) or DeLancey's (27) published reports.

The vagina will lose approximately 70% of its support upon removal of the uterus. Therefore, re-suspension of the vaginal cuff should be considered an integral part of the hysterectomy. As this study documented, the uterus should be excised very precisely at the fornices to preserve the vaginal configuration and length; such excisions are crucial for placing the vagina parallel to the rectum/levator plate and elongating the vagina to maintain its natural configuration. The retroperitoneal prophylactic reconstruction of both the rectovaginal space and the pouch of Douglas cannot compromise the length, width, or topography of the vagina, or alter vaginal angulation. The closest anatomically neighboring uterine-vaginal suspensory structures must be used to accomplish this (neither the round ligament nor the infundibulopelvic ligament fall into this category). Any anatomical element of the suspension that may elevate or push the vagina away from its natural location

must be avoided, and the endopelvic fascia must cover the previously denuded upper anterior vaginal wall.

The new technique for culdoplasty and colpopexy at the time of L-TAH, presented here, differ from the laparotomy classic technique by: 1) performing this prophylactic operation retroperitoneally, 2) not incorporating the round, uteroovarian, infundibulopelvic ligaments, and 3) involving the Fallopian tube. The detailed differences between the new and old existing classic technique are depicted in Table I.

Acknowledgment

The author would like to express his appreciation to Dr. Bogdan Michalski, for assisting in the preparation of medical illustrations.

References

1. Semm K. Intrafascial hysterectomy. WISAP, Germany 1993; pp. 15: 51–2.
2. Nezhat CR, Nezhat FR, Silfen SL. Laparoscopic hysterectomy and bilateral salpingo-oophorectomy using multifire GIA surgical stapler. *J Gynecol Surg* 1990; 6: 287–9.
3. Magos AL. Laparoscopically assisted vaginal hysterectomy *Lancet* 1991; 338: 1091–2.
4. Padiol JG, Sotolongo J, Johnson C, Osborne NG. Laparos-

- copy-assisted vaginal hysterectomy: report of seventy-five consecutive cases. *J Gynecol Surg* 1992; 8: 81–3.
5. Daniell JF, Kurtz BR, McTavish G et al. Laparoscopically assisted vaginal hysterectomy: The initial Nashville, Tennessee, experience. *J Reprod Med* 1993; 38 (7): 537–42.
 6. Jones RA. Laparoscopic hysterectomy – a technique. *Aust NZ J Obstet Gynaecol* 1993; 33 (3): 290–5.
 7. Bruhat MA, Wattiez A, Mage G et al. Laparoscopic hysterectomy. Polyclinic series. *References Gynecol Obstet* 1994; 2: 56–9.
 8. Langebrekke A, Skar OJ, Urnes A. Laparoscopic hysterectomy. Initial experience. *Acta Obstet Gynecol Scand* 1992; 71: 226–9.
 9. Nezhat F, Nezhat C, Gordon S, Wilkins E. Laparoscopic versus abdominal hysterectomy. *J Reprod Med* 1992; 37: 247–50.
 10. Mage G, Masson FN, Canis M et al. Laparoscopic hysterectomy. *Curr Opin Obstet Gynecol* 1995; 7: 283–9.
 11. Semm K. Hysterectomy via laparotomy or pelviscopy. A new CASH method without colpotomy. *Geburtshilfe Frauenheilkd* 1991; 51 (12): 996–1003.
 12. Vietz PF, Ahn TS. A new approach to hysterectomy without colpotomy, pelviscopic intrafascial hysterectomy. *Am J Obstet Gynecol* 1994; 170: 609.
 13. Pelosi MA, Pelosi MA III. Laparoscopic supracervical hysterectomy using a single-umbilical puncture (mini-laparoscopy). *J Reprod Med* 1992; 37: 777–84.
 14. Lyons T. Supracervical laparoscopic hysterectomy. A comparison: Morbidity and mortality results with LAVH. *J Reprod Med* 1993; 38: 763–4.
 15. Ostrzenski A, Klimek M, Wojtys A. Video laparoscopic modified hysterectomy with vaginal vault suspension. *Pol Gynecol* 1992; 63: 365–9.
 16. Ostrzenski A. Video laparoscopic vaginal cuff suspension after hysterectomy. A review of ten cases. *J Obstet Gynecol (UK)* 1993; 13: 456–9.
 17. Ostrzenski A. Laparoscopic panhysterectomy with reconstructive posterior culdoplasty and vaginal vault suspension. New York, USA. Medical Science Publishing, Inc. 1993.
 18. Ostrzenski A. Laparoscopic total abdominal hysterectomy by suturing technique, with no transvaginal surgical approach: a review of 276 cases. *Int J Gynaecol Obstet* 1996; 55: 247–57.
 19. Garry R, Riech H. *Laparoscopic Hysterectomy*. Oxford: Blackwell 1993.
 20. Ostrzenski A. A new, simplified posterior culdoplasty and vaginal vault suspension during abdominal hysterectomy. *Int J Gynaecol Obstet* 1995; 49: 25–34.
 21. Ostrzenski A. A new, simplified posterior culdoplasty and vaginal vault suspension during abdominal hysterectomy. Abstracted in: *Obstet Gynecol Survey* 1996; 51 (2): 94–5.
 22. Okabayashi H. Radical abdominal hysterectomy for cancer of the cervix uteri. *Surg Gynecol Obstet* 1921; 23 (4): 335–401.
 23. Ostrzenski A. Endoscopic pelvic herniorrhaphy with CO₂ laser. *Gynecol Endoscopy* 1992; 1: 95–8.
 24. Wilensky AV, Kaufman PA. Vaginal hernia. *Am J Surg* 1940; 49: 31–4.
 25. Nichols DH. Types of enterocele and principles underlying the choice of operation for repair. *Obstet Gynecol* 1972; 40: 257–62.
 26. Shull BL, Capen CV, Riggs MW, Kuehl TJ. Preoperative and postoperative analysis of site-specific pelvic support defects in 81 women treated with sacrospinous ligament suspension and pelvic reconstruction. *Am J Obstet Gynecol* 1992; 166: 1764–8.
 27. DeLancey JOL. Anatomic aspects of vaginal eversion after hysterectomy. *Am J Obstet Gynecol* 1992; 166: 1717–28.

Address for correspondence:

Adam Ostrzenski, M.D., Ph.D.
 Professor of Gynecology & Obstetrics
 1002 22nd Street, N.W.
 Washington, D. C. 20037
 USA