

MODULE I

- **THE LABIA MINORA**
- **THE CLITORAL PREPUCE**
- **THE CLITORAL FRENULUM**

PROGRAM online COURSE/WORKSHOP

The labia minora:

- *LABIOREDUCTION*
- *LABIOPLASTY*

The prepuce of the clitoris

- *HOODOREDUCTION*
- *HOODOPLASTY*

The frenulum of the clitoris

- *FRENULOREDUCTION*
- *FRENULOPLASTY*

The Cosmetic-Plastic Gynecologic Course/Hands-on-Workshop teaches the principles of general cosmetic surgery and safe step-by-step gynecologic cosmetic-plastic techniques to improve participant surgical skills. The following specialty will benefit from this medical, educational event:

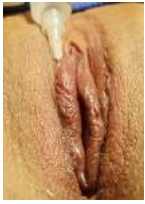- Gynecologic surgeons
- Plastic surgeons
- Urologic surgeons
- General surgeons
- Dermatologic surgeons.

Part I presents cosmetic surgery's general principles, the main branch's anatomy of the labium minus, the prepuce and the frenulum of the clitoris, and Ostrzenski's new structure discoveries within the frenulum of the clitoris. The course/workshop teaches how to apply safe surgical techniques and help recognize safe v/s harmful surgical procedures.

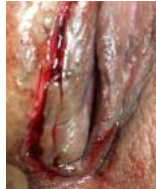Part II teaches practical hands-on gynecologic surgical techniques on commercially available animal flesh. The course/workshop is designed and presented by Prof. Ostrzenski to teach cosmetic surgery of the labia minora, the prepuce, and the clitoris frenulum.

In this section, a participant will learn:

- Local anesthesia



- Cosmetic incision and different excisions
- Cosmetic surgical dissections

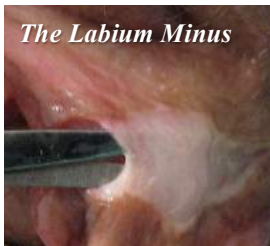

- Cosmetic suture selections and closing techniques
- Ostrzenski's delamination of the labia minora
- Ostrzenski's new clitoral hoodoreduction and hoodoplasty
- Ostrzenski's new fenestration labioreduction
- Ostrzenski's modified arch labioreduction
- Abrupt and straightforward labioreduction
- Prepuceioplasty
- Frenuloreduction and frenuloplasty
- Anterior and posterior commissuroplasty

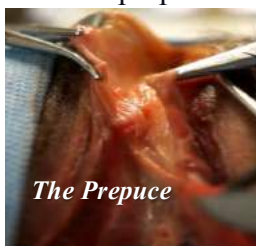
LEARNING OBJECTIVES:

- Definitions of Cosmetic and Plastic Gynecology
- Informed Consent
- Gross, Functional, Topographic, and Surgical Anatomy of

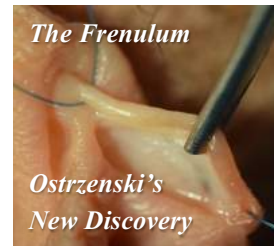the labia minora



the prepuce

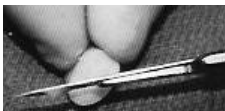

the frenulum



Cosmetic Surgery Principles:

- Cosmetic incisions



- Hidden incisions
- Cosmetic excisions

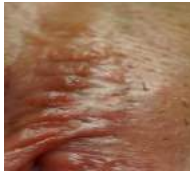- CPG surgical instruments



- Sutures and suturing



- Cosmetic types of skin closure
- Cosmetic types of surgical knots
- Skin adhesives
- Creating fine-line scar
- How to avoid “dog-ear”, “railroad tracks”, and “trapdoor” complications



- Skin flap advancements
- Recognizing unfavorable anatomic areas prone to post-operative wrinkle, widening scar, keloids, or hypertrophic scars
- Identifying a relaxed skin tension line
- Acknowledging the fact that female genital organs are prone to severe edema
- Recognizing factors affecting the final appearance of a fine-line scar
- Recognizing:
 - * Differences skin types and textures
 - * Tension on closure
 - * Patient’s systemic condition

Rotating flaps

- Rotating flaps
- Advancement skin flaps:
 - o Directly forward advancement
 - o Single-pedicle advancement
 - o V-Y advancement
 - o Bipedicle advancement
- Z-plasty and W-plasty for scar size reduction

Adipose tissue as natural filler:

- Transposition
- Transplant

Wound healing:

- Cytokines

- Growth factors

Labiorreduction of the Labium Minus: Main Structure, the Prepuce, and Frenulum

- Microsurgical technique application in cosmetic-plastic gynecology
- Pre- and post-operative cares in cosmetic-plastic gynecology

Safe Surgical Techniques for labiorreduction of the Labia Minora:

- Arch Labiorreduction (Ostrzenski's Modification)
- Posterior Wedge Resection (Martincik & Malinowski)
- Central Partial Delamination (A-P-D-epithelialization [Choi & Kim])
- Fenestration Labiorreduction (Ostrzenski) – ranking 2nd in the world scientific-clinical article

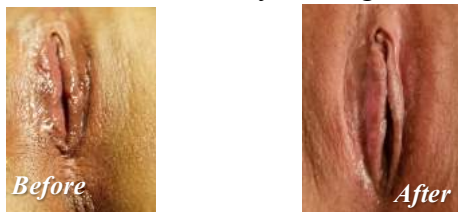


Harmful Surgical Techniques for labiorreduction of the Labia Minora:

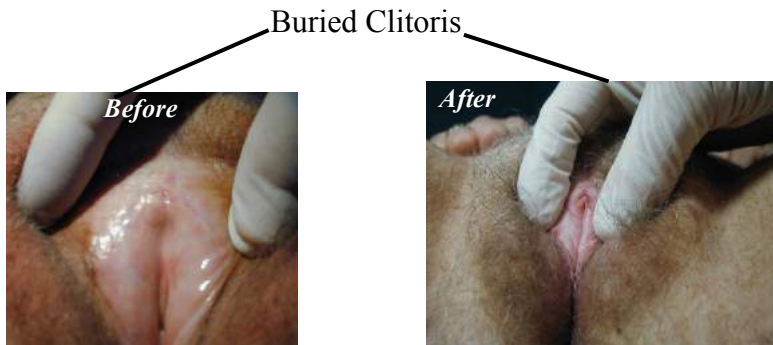
- Abrupt Labiorreduction
- Straightforward Amputation
- Central V-Plasty
- W-Plasty
- Nymphectomy with 90° Z-Plasty
- Inferior V-plasty

Ostrzenski's Corrective Labioplasty for a Labium Minus Botched Surgery

- Ostrzenski's Labiolysis Surgical Technique



- Prepuceplasty
- Frenuloplasty
- Ostrzenski's Hydrodissection with Reverse V-plasty for the Phimotic or Buried Clitoris

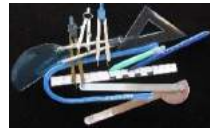

- Commissuroplasty
- Corrective Surgery for Labial Over-resections
- Labium Minus Expansion Technic for Corrective Surgery

- Corrective Surgery for Iatrogenic Neuropathy
- Corrective Surgery for Iatrogenic Pudenda Neuralgia
- Decompression of the Clitoral Glans and Body

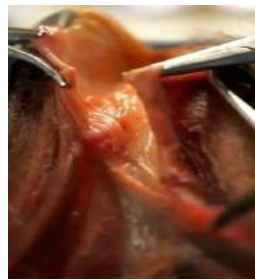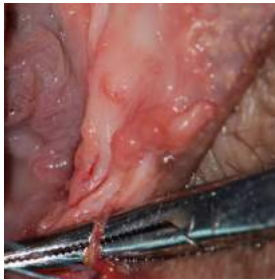
Avoidable Surgical Complications

**SCHEDULE
PART I - DIDACTIC SESSION**



6:00 – 6:45 ***Introduction and Principles of Cosmetic Surgery***

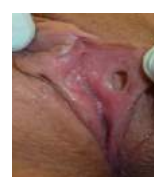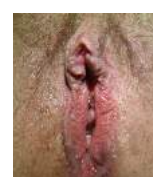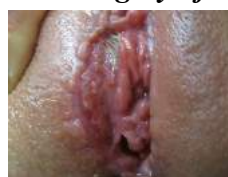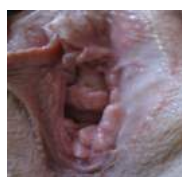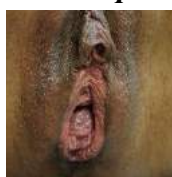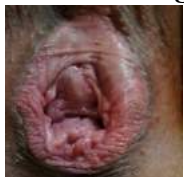6:45 – 7:00 ***Gross, Functional, Topographic, and Surgical Anatomy of the Labia Minora, the Prepuce & Frenulum***



7:00 – 7:10 Break

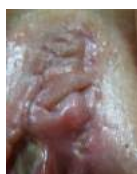7:10 – 7:45 ***Safe & Harmful Surgical Techniques for Labioreduction of the Labium Minus***
Main Structure

7:45 – 8:30 ***Iatrogenic Complications and Corrective Surgery of the Labia Minora***

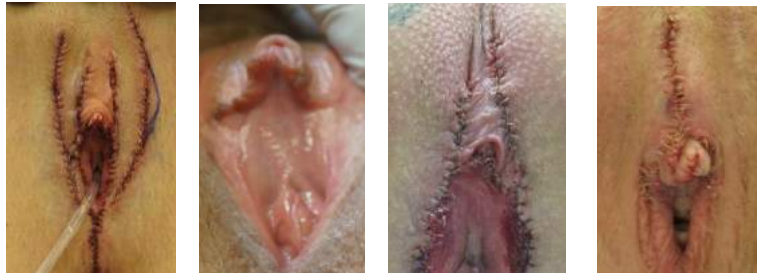

8:30 – 8:40 Break

8:40 – 8:25 ***The Clitoral Prepuce: Safe & Harmful Techniques, & Corrective Surgery***



8:25 – 9:10 *The Clitoral Frenulum: Safe & Harmful Techniques, & Corrective Surgery*



9:10 – 9:20 Break

9:20 – 10:05 *Group Discussion*

10:05 – 10:15 *ASK PROFESSOR*

10:15 – 10:30 Break

PART II - HANDS-ON LABORATORY TRAINING

10:30 – 12:15 Dry Laboratory

DRY LABORATORY: Prof. Ostrzenski designed this education model to help a surgeon understand a surgical concept of a particular surgical technique. A surgeon draws a picture of a surgical technique of the labia minora, clitoral prepuce, and clitoral frenulum and cuts-out it to learn the incision lines.

Prof. Ostrzenski himself supervises surgeons until the surgical technique is done correctly. This educational process allows doctors to understand the concept of a particular procedure and familiarize themselves with the step-by-step surgical intervention.

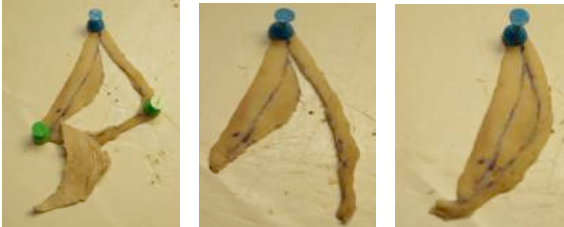

12:15 – 1:00 Break

1:00 – 2:30 Wet Laboratory

WET LABORATORY is designed by Prof. Ostrzenski and provides hands-on training for surgeons. Commercially available animal flesh is used to teach incision, excision, cosmetic surgical dissection, cosmetic suturing methods, selecting the type of suturing material, needle, and instruments, and executing surgical techniques of the labia minora, clitoral prepuce, and clitoral frenulum.

Ostrzenski's New Fenestration Labioreduction



FOR REGISTRATION CLICK HERE

PAYMENT