European Journal of Obstetrics & Gynecology and Reproductive Biology 267 (2021) 42–48

Contents lists available at ScienceDirect

European Journal of Obstetrics & Gynecology and Reproductive Biology

journal homepage: www.elsevier.com/locate/euro

Pelvic Organ Prolapse Quantification (POP-Q) system needs revision or abandonment: The anatomy study

Adam Ostrzenski

Padua University, Italy
Institute of Gynecology, Inc., 7001 Central Ave., St. Petersburg, FL 33710, USA

ARTICLE INFO

Article history:
Received 30 June 2021
Revised 26 September 2021
Accepted 13 October 2021

Keywords:
Urogenital hiatus in women
Perineal body anatomy in women
Perineal body defects in women
Pelvic organ prolapse quantification
Rectovaginal anatomy

ABSTRACT

Objective: To examine the female urogenital hiatus (UGH) and perineal body gross and topographic anatomy; to analyze the POP-Q recommendation for evaluating UGH and PB.
Study design: A prospective case series study on fifteen fresh human adult female cadavers was conducted in international settings. Stratum-by-stratum, macro-, and micro-anatomical dissections to study the UGH and PB gross-topographic anatomy. In addition, HGH and PB descriptive anatomy presented in the medical literature were analyzed. The primary outcome measured the accuracy of POP-Q in the assessment of UGH and PB. Additionally, digital photos were taken to document UGH and PB gross and topographic anatomy.
Results: The present study confirmed that the urogenital hiatus was a well-described structure in the medical literature. It is an oval-shaped structure that originated at the inferior pubic bone and was inserted into the posterior anal wall and superior surface of the PB. In all subjects, the location of UGH was in the Retzius space. Therefore, the recommendation by the POP-Q to evaluate UGH from the middle urethral meatus to the posterior hymeneal ring was incorrect because it did not accurately reflect the total longitudinal diameter of UGH.

The PB topographic anatomy was not appropriately described in the literature. PB was an oval-shaped, solid, muscular mass without the central point of the perineum or fascia and rested between the posterior-distal vaginal wall and the anterior anorectal wall in a horizontal orientation and was not a part of the posterior perineum as the POP-Q system indicated. Therefore, a vertical measurement of the perineal body as recommended by POP-Q was impossible to obtain due to its horizontal orientation under the posterior-distal vaginal wall; PB had to be measured horizontally. The median length was 4.2 c m ± 1.6 (SD).
Conclusions: The POP-Q system does not adequately assess UGH and PB and needs revision.

Introduction

The urogenital hiatus (UGH) and the perineal body (PB) in women are integral anatomical landmarks of the Pelvic Organ Prolapse Quantification (POP-Q) system for evaluation [1]. For over 25-year, leading gynecologic, urogynecologic, urologic, and urinary continence societies have endorsed this system for clinical assessment and medical research.

Scientific-clinical documentations exist that UGH enlargement is associated with pelvic organ prolapse and can predict a surgical failure [2–6]; therefore, intimate anatomical knowledge about UGH is necessary for appropriate clinical evaluations of this structure. Furthermore, the POP-Q System places the PB within the posterior perineum and recommends evaluating it vertically [1].

Macalister from England first describes PB location between the posterior-distal vaginal wall and the upper half of the anterior recto-anal area in a horizontal orientation and terms this structure as the "perineal body" [7]. He also provided illustrations of PB. Medical researchers confirm these findings [8–10]. However, many publications and traditional textbooks place PB within the posterior perineum [1,11,12]. So far, this anatomical controversy has not been resolved.

Furthermore, the PB creates an anatomical barrier to stabilize and prevents the posterior-distal vaginal wall and the upper anorectal region from prolapsing. Dynamic MRI studies verify that the PB structure occupies the space between the posterior-distal vaginal wall and anorectal area in the horizontal orientation [9,13,14].

E-mail address: ao@baymedical.com

https://doi.org/10.1016/j.ejogrb.2021.10.016
2215-1532/

The rationale for conducting the current investigation is to resolve the anatomical controversy surrounding the PB's topographic location, orientation and revisit the urogenital hiatus anatomy and its evaluation. Therefore, the objectives are to examine the female urogenital hiatus anatomy, document the perineal body gross and topographic anatomy, and scientifically scrutinize the POP-Q recommendation for evaluating UGH and PB.

Material and methods

The author conducted a case serials study on fifteen fresh adult human female cadavers at the Forensic Medicine Department. The Institutional Bioethics Committee of the local medical university approved this investigation (AKBE 146/12). Unfortunately, the deceased's medical records were not available due to the Department of Forensic Medicine's type of medical services. Therefore, this author performed all inspections, measurements, stratum-by-stratum, macro-, and micro-dissections without applying blunt dissections and using 3.5–4.0 surgical loupe magnifications.

Inclusion/exclusion criteria

Female fresh adult human cadavers were selected consecutively for the present study. Those subjects whose uterus was intact and the uterine cervix was above the "Aa point" when the POP-Q system was applied were included. Subjects with a) a prior hysterectomy; b) a tumor or other genital lesions; c) enlarged lymph nodes; d) anatomical aberrations of the pelvic diaphragm and anorectal regions or lower genital tract, e) rape or incest associated with homicide were excluded. Those women who demonstrate uterine prolapse beyond the hymeneal ring were also excluded.

Urogenital hiatus anatomical dissection and evaluation

The Retzius space was entered, and then the transversalis fascia was stripped off from the pubic bones. This dissection was continued until the neurovascular bundle entering the obturator foramen was visualized. Next, the urachal fold, the vesical fascia, and both ureters were dissected off; the urinary bladder was mobilized and sharply separated from the urethra. Finally, the vaginal tube was resected above the UGH — these maneuvers allowed access to the urogenital hiatus. The pubovaginalis fiber muscles were identified, and the proximal–distal edges were marked with a skin marker. The postmortem measurement of the urogenital hiatus length was taken from the anterior-inferior pubic bone to the ventral surface of the perineal body. The width was obtained transversely from the lateral-posterior vaginal wall fusion with the pubovaginalis muscle just on the anterior surface of the pubovaginalis muscle.

Perineal body anatomical dissection and evaluation

A small incision was made on the proximal inner part of the hymeneal ring at 3–4 o'clock and extended to approximately 6 cm towards the uterine cervix. The vaginal wall's full thickness was dissected and retracted upwards. Then, the posterior-distal vaginal wall was dissected off from the perineal body's anterior surface. Laterally, the dorsal perineal membrane and the superficial transverse perineal muscle (STPM) were dissected from the PB. The dissection continued until the lateral surfaces of the PB were released from the adjacent tissues, and the posterior perineal body was exposed by dissecting it from the rectovaginal septum, internal anal sphincter muscle, and the anterior anorectal. The PB was freed from the adjacent anatomical structures. The PB's identification stopped at the level of the anterior anorectal wall. Determining whether the site-specific defects were not related to dissections, the edges of defects were examined using a magnification loupe to observe the thickness and defects' edges. The digital photograms were taken to document the gross and topographic anatomy. The horizontal measurements of the PB were obtained from the inner hymeneal ring to the apex of PB. The lateral extensions were not included in the measures.

Literature search

The author carried out the medical literature's electronic and manual searches for UGH and PB pathological, gross, topographic anatomy articles, conference proceedings, and specializing websites. The Medical Subject Headings (MeSH) were used in gathering relevant publications. Following keywords were used: female urogenital hiatus gross anatomy, female urogenital hiatus topographic anatomy, female urogenital site-specific defects, female urogenital repair, female perineal body anatomy, anorectal anatomy; vaginal anatomy; female perineal body gross anatomy; perineal body topographic anatomy, vaginal introitus; perineal body location; rectovaginal septum; perineal body histology; female perineal body; perineal body defects; vaginal wall defects; posterior vaginal colporrhaphy; female posterior perineum; posterior perineoplasty; modified posterior perineoplasty; vaginal tightening procedure.

Results

The present study included fifteen fresh adult human female cadavers; nine out of fifteen (60%) did not demonstrate pelvic organ descent or prolapse with negative a tenaculum cervical traction tests. Four remaining subjects (40%) presented with vaginal apex descent. Thus, the present study confirmed the accurate gross and topographic anatomical descriptions in the medical literature of the urogenital hiatus in women. However, the recommendation of POP-Q about the evaluation of UGH and PB was not correct. The measurement points of UGH were wrong, and the PB anatomical topography was bad too. Subsequently, a new external measurement method was developed for female UGH and PB.

The gross and topographic anatomy of the urogenital hiatus

The urogenital hiatus was a U-shape structure with the natural passage for the urethra, vagina, and rectum. UGH was located on the anterior pelvic floor. The pubovaginalis muscle fibers looped the posterior vaginal wall, inserted into the anterior-inferior pubic bone, and attached to the vaginal surgical fascia (the vaginal adventitia)—the perineal membrane ran from one side of the ischiopubic ramus bone to another and supported UGH. The fibers of the puborectalis looped the posterior anal wall. The perineal membrane was intimately fused with the pubic arch bone, the symphysis pubis, the inferior ischiopubic ramus, and anteriorly, combined with the vaginal vestibular bulbs' bifurcation Fig. 1A and Fig. 1C. The deep perineal pouch houses the urethral compressor muscle, the urethrovaginal sphincter muscle—between the pelvic diaphragm and the perineal membrane's superior surface, the perineal branch of the pudendal nerve were located. During the anatomical dissection, the obturator internus, the piriformis muscle, the deep perineal pouch, and the perineal membrane were identified. Defects within the perineal membrane occur and cause UGH enlargement, Fig. 1C. Additionally, the paravaginal defect can also widen the UGH, Fig. 1B. The levator ani sling, ligaments, and fascia formed UGH. In this study, a new external measure was developed, reflecting the actual anatomical size of UGH. The measurement of UGH was taken from the external inferior pubic bone to the posterior anal wall, Fig. 2.

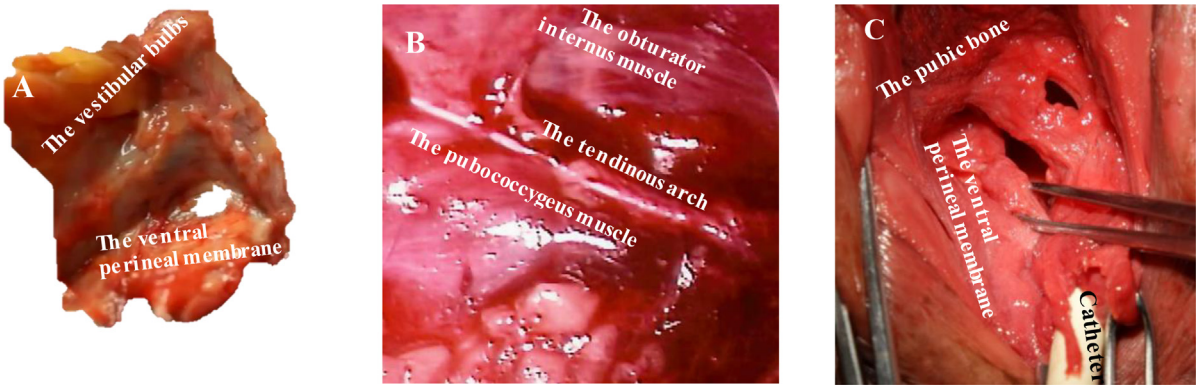

Fig. 1. The ventral perineal membrane, its defects, and paravaginal defects A. Intact the perineal membrane with adjacent structures B. The obturator internus muscle defect and separation of pubococcygeus and iliococcygeus muscles from the arch tendinous fascia pelvis (the white line) C. The ventral perineal membrane (PM) fuses with the pubic arch and the ischiopubic ramus. Old (thick and everted edges) site-specific defects are depicted.

For women who did not demonstrate vaginal descent or prolapse (n = 9) the median hiatus length was 5.6 cm ± 1.7 standard deviation (SD). For subjects who were identified with vaginal descent, the median length was 7. 4 cm ± 12.5 (SD). The median width 3.2 ± 0.61 cm (SD). The width enlarged to the median width of 5.2 ± 0.3. The puboanal, puboperineal, pubovaginal muscles originated from the anterior-inferior surface of the pubic bone. They traversed medially and fused with the puborectalis muscle in the vicinity of the vaginal wall. These pubovisceral muscle subdivisions at the origin were seen, and origin and insertion could also be identified. The puboperineal muscle was observed ventrally to the perineal membrane, and the puboanal fibers were recognized at the upper level of the external anal sphincter.

The most common defect that caused the urogenital hiatus widening was a separation of the levator ani muscles from the arch tendinous fascial pelvis, Fig. 1B.

The gross and topographic anatomy of the perineal body

The PB rested under the posterior-distal vaginal wall and raised the posterior distal vaginal wall in the horizontal orientation. Fig. 2. The PB site-specific defect could cause irregularity on the surface of the vaginal mucosa, Fig. 2. The PB proximal, lateral, and distal boundaries were visible on the vaginal mucosa, Fig. 2.

Upon identifying the full lateral thickness of the vaginal wall, Fig. 3, the vaginal adventitia stratum was dissected from the superior surface of the PB, Fig. 4 and Fig. 5. The perineal body was an oval shape and solid muscular mass without the fascia, Fig. 5A. The PB extended from the inner hymeneal ring on an average of 4.2 cm, outspread to the anorectal junction, and fused with the rectovaginal septum (Denonvilliers' fascia). The anterior-proximal apex of the perineal body was attached to the 1/3 posterior-distal vaginal wall. Anteriorly, the superficial fascia of the levator

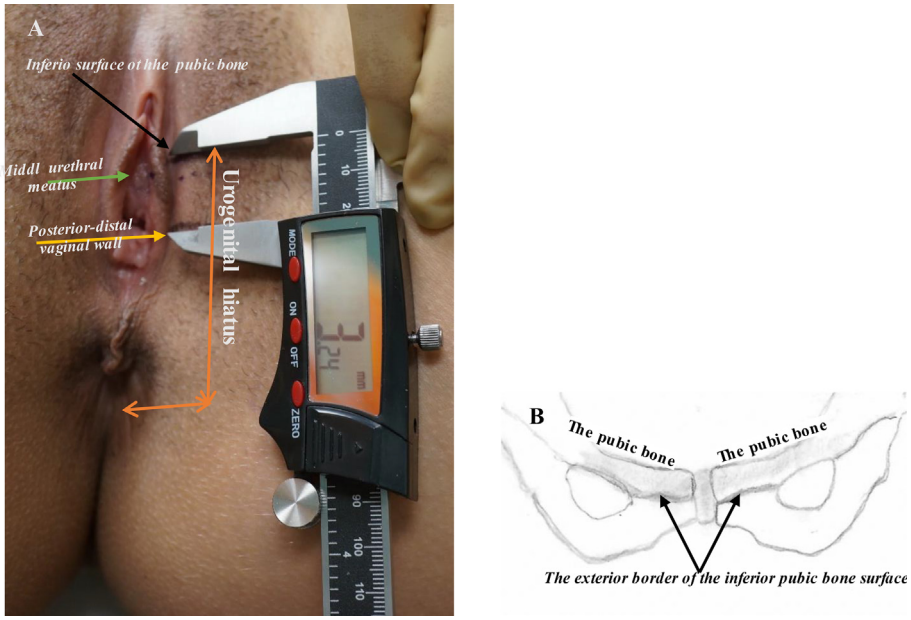

Fig. 2. The proposed external measurement of the urogenital hiatus. A. The external measurement of the female urogenital hiatus from the palpable inferior surface of the pubic bone (the black arrow) to the posterior anal wall (the smaller brownish arrow). The dotted line between the big jaws of the caliper depicts the lateral extension of the middle urethral meatus. The diameter from the upper lower big jaws of the caliper to the posterior anal wall (the brownish long arrow) represents the urogenital hiatus. B. The illustration of the posterior-inferior border's surface of the pubic bone is presented. From one side of the reference point (the black arrowhead), the measurement is taken. The measure of urogenital hiatus is initiated from that continued to the posterior anal wall.

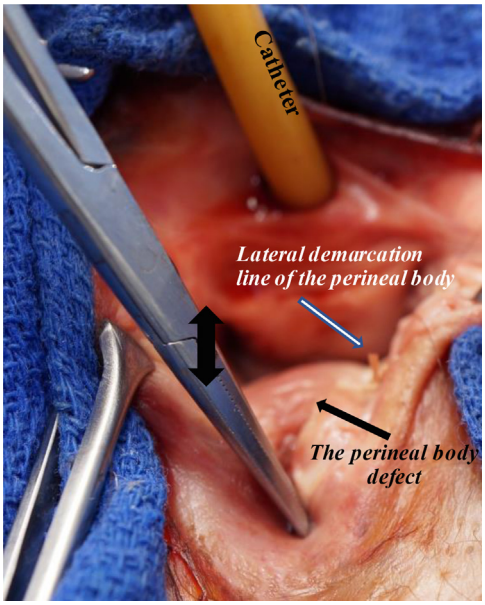

Fig. 3. Identifying the perineal body location. The instrument points out the distal boundary of the perineal body and the naturally elevated posterior-distal vagina by the perineal body. Above the instrument's tip, the perineal body's site-specific defect shows (the black arrow). The perineal body's lateral demarcation line is visible on the lateral-posterior-distal vaginal mucosa (the white arrow), and the apex is also identifiable.

ani muscle was inserted into the posterior perineal body. Laterally, the PB fused intimately with the lateral vaginal wall and pubovaginalis muscle. The internal anal sphincter muscle, the dorsal perineal membrane, and the superficial transverse perineal muscle (STPM) suspended the perineal body laterally to the ischiopubic rami. Posteriorly, the perineal body was attached to the lower segment of the anterior anorectal wall, inserted into the STPM, bulbocavernosus muscle, and the posterior-proximal perineal skin, the pubovaginalis, and the puborectalis muscle. The pubovaginalis muscle and puborectalis muscle connected the PB to the urogenital hiatus and levator hiatus.

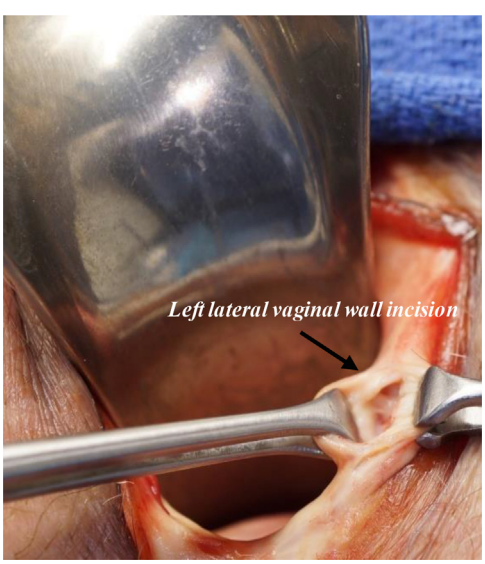

Fig. 4. The vaginal wall initial incision. On the left lateral vaginal wall, a small incision is created close to the inner part of the hymeneal ring. The entire thickness of the vaginal wall grasped between the jaws of surgical instruments.

The central point of the perineum and the fascia were absent within the PB. In the horizontal orientation, the PB height was between 2.6 cm and 5.8 cm with the median 4.2 cm ± 1.6 (SD); the width ranged from 2.3 cm to 3.7 cm, median 2.8 cm ± 0.5 cm (SD); the thickness was between 1.2 cm and 1.8 cm, median 1.5 c m ± 0.3 (SD). Following the POP-Q system, PB's vertical measurements were impossible because this structure was located in horizontal orientation, Fig. 1. The PB variation in anatomic findings between cadavers was in size and thickness. In all subjects, the PB location was always under the posterior-distal vaginal wall and in the horizontal orientation, and there was no difference in originations and insertion points.

Discussion

Principal findings

The current study confirmed the gross and topographic anatomy description of the female UGH in the literature; however, the POP-Q System recommendation to assess UGH and PB was inaccurate. Additionally, the study established that the site-specific defects within the obturator internus muscle or separation of the pubococcygeus muscle from the arch tendinous fascia pelvis could cause UGH enlargement, Fig. 1B. Site-specific defects within the ventral perineal membrane also affect the size of UGH, Fig. 1C. UGH's adequate external clinical measurement is possible, taking it from the inferior pubic bone to the posterior anal wall, Fig. 2.

The perineal body naturally elevates the posterior-distal vaginal wall, and boundaries were visible on the vaginal mucosa anterior surface, Fig. 3. The anterior PB site-specific defect caused, in some cases, the vaginal mucosa anatomical irregularity, Fig. 3. The present study showed that the PB occupied approximately 1/3 of the posterior-distal vaginal wall and this finding also eliminated the option to measure the PB vertically.

Therefore, the POP-Q System recommendation to measure PB vertically did not reflect the perineal body but represented the posterior perineum.

Some traditional textbooks described the PB as connected to the deep transverse perineal muscle and the posterior perineal musculatures [15,16]. The term "the deep, transverse perineal muscle" does not exist, as Oelrich documented it [17]. The present study confirmed no PB fascia is present and the absence of a central point of the perineum [18]. The posterior vaginal introitus fuses with the distal PB [19–21].

A few scientific-clinical articles on the PB limited a meaningful comparison between other studies and the present investigation. Maldonado et al. used preserved cadavers and measured the PB in horizontal orientation from the PB apex to the hymeneal remnants. This study's findings are compatible with the current research because cadaveric tissue shrinks considerably more in fixed cadavers than in a fresh corpse [22]. Also, the present study confirmed other authors' findings that the PB was horizontal orientation and located under the posterior vaginal wall [7–10,22].

Utilizing the POP-Q System for PB clinical evaluation and research is wrong since the POP-Q concept is ill-designed from a gross and topographic anatomy point of view. One cannot evaluate PB by taking an external vertical measurement since this structure is located under the posterior-distal vaginal wall in the horizontal orientation. Since PB location and orientation, POP-Q System can not obtain PB's length, width, or depth dimensions by the vertical measure because it is physically impossible to execute due to PB horizontal orientation.

The current study's findings differ from other investigations by showing that the PB structure's vertical measurement is incorrect as the POP-Q system recommends. Furthermore, site-specific

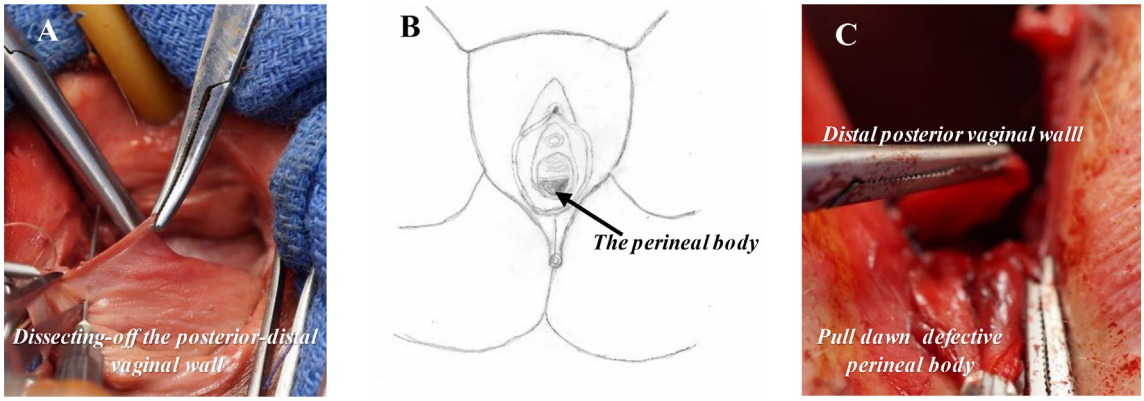

Fig. 5. The perineal body identification A. Dissecting off, the posterior-distal vaginal wall from the anterior surface of the perineal body is depicted. B. The grasping instrument stretches the perineal body and brings it downward. The groove dividing the perineal body is the anatomical defect usually associated with the posterior vaginal wall prolapse (rectocele). The dissected off the posterior-distal vaginal wall is stretched and raised by a grasper above the perineal body.

defects within the PB anterior and posterior surfaces differ, making it also a discovery. MRI and endoanal ultrasonography can demonstrate UGH and PB location and site-specific defects within the anal wall, UGH, and the PB [23].

All clinical-scientific articles used only the perineal body illustration. No photograms were used in the publications to depict the natural appearance of PB. Thus, this situation hampers the adequate teaching of anatomy and surgery. This study fills this gap by publishing PB photograms, Fig. 3, Fig. 5B, and Fig. 6. Moreover, the present investigation expanded our knowledge about the perineal body and its inappropriateness of vertical location and measurements and established that horizontal measurement provided adequate diameters.

The meaningful comparison between the POP-Q System and UGH's newly developed external measurement is difficult because POP-Q recommends examining a patient in a) the supine position; b) standing; c) a patient straining. In the cadaveric study, only a prone position is applicable. However, the anatomy assessment between those two systems is possible. The POP-Q System recommends evaluating the female genital hiatus from the mid-urethral meatus to the posterior margin of the hymen in the midline, Fig. 7A [1]. This measurement reflects the fragment of the UGH length, Fig. 7B, since UGH stretches from the anterior-inferior pubic bone to the posterior rectal wall.

Additionally, the external urethral meatus as a reference point is inappropriate because the urethra is mobile, and the posterior-inferior pubic bone is a fixed reference point. Therefore, POP-Q evaluation of UGH is the artificial anatomical concept that disregards the gross anatomy. Contrary, a newly developed UGH evaluation concept incorporates the total length of this structure from the posterior-inferior pubic bone (the fixed reference point) to the posterior anal wall, 7B. The posterior-inferior pubic bone is straightforward to identify by palpation, and the posterior anal wall is also easy to recognize by visualization and palpation.

POP-Q System also evaluates the perineal body inappropriately. In this system, the perineal body assessment is assessed vertically from the posterior margin of the hymen to the mid-anal orifice,

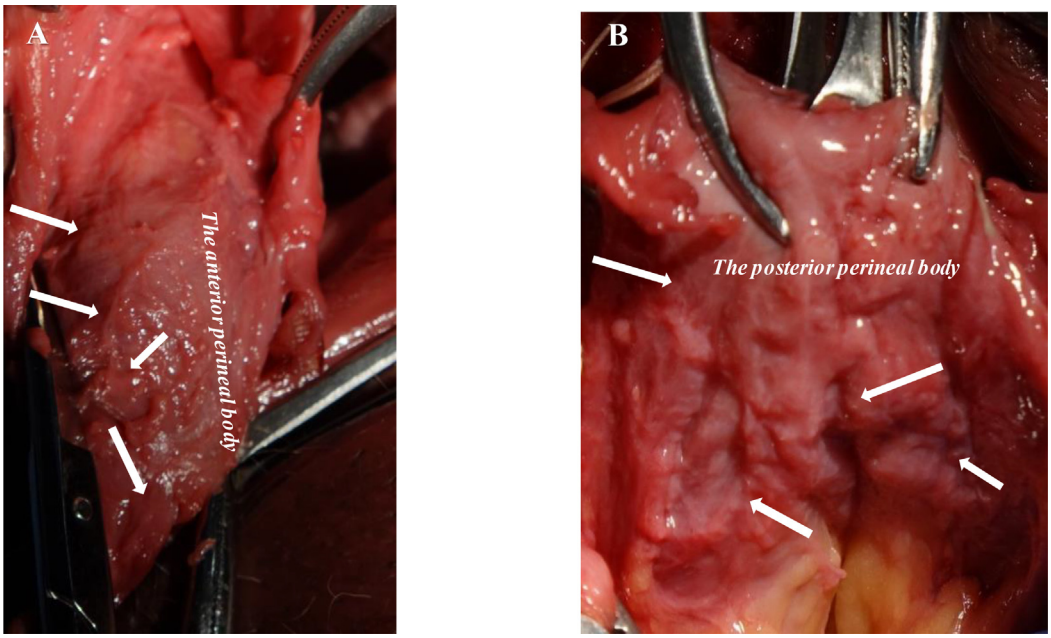

Fig. 6. The anterior vaginal surface of the perineal body A. The posterior vaginal wall is dissected from the anterior perineal body that resembles a pear-shaped appearance. Many site-specific defects with thick edges that protruding from the surface of the perineal body (white arrows) are depicted. B. The posterior perineal body dissected off from the internal anal sphincter muscle and rectovaginal septum demonstrate multiple site-specific defects with thick and everted edges signifying the long-lasting healing process of defects (white arrows), and no dissections were causing these defects.

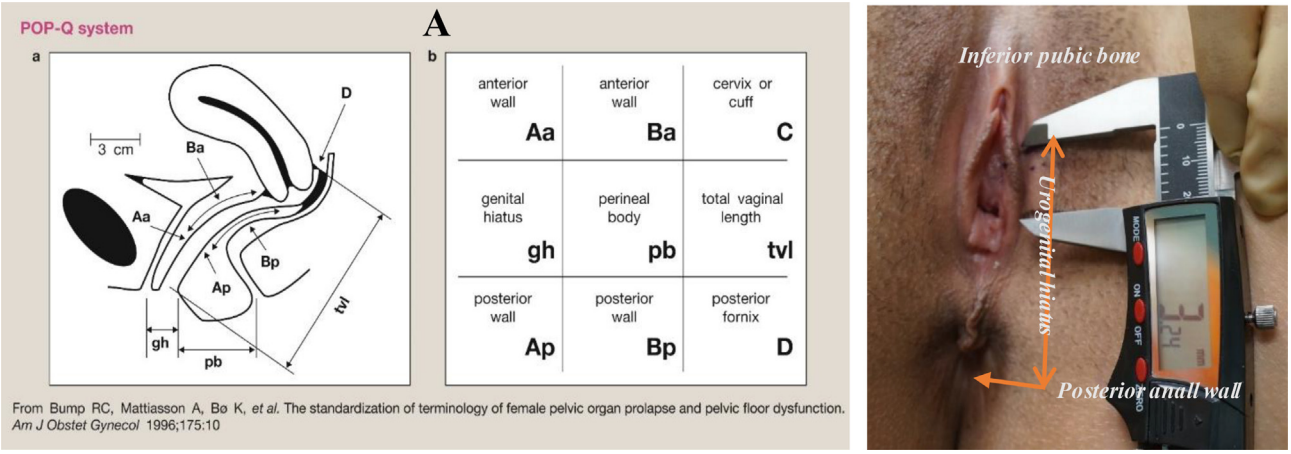

Fig. 7. Comparison between the POP-Q System and proposed new external measurement A. The POP-Q recommends measuring the urogenital hiatus (gh) from the middle of the urethral meatus to posterior margin of the hymen in the midline. The perineal body (pb) measurement is taken vertically from the posterior margin of the hymen to the mid-anal orifice. B. The new proposed evaluation of the female urogenital hiatus is from the posterior-inferior surface of the pubic bone (a fixed reference point) to the posterior anal wall.

Fig. 7A [1]. However, this suggestion is against the natural topographic anatomy of the perineal body, located horizontally. Therefore, vertical assessment of the perineal body is physically impossible. Furthermore, the perineal body is not a part of the posterior perineal musculature, and POP-Q identifies PB as a part of the perineum, Fig. 3 and Fig. 5B.

Strengths and limitations

The present study showed that the female urogenital hiatus assessment by POP-Q was not appropriate. Furthermore, it resolved the controversy surrounding the topographic anatomy of the PB. Additionally, the current study established that the PB horizontal measurement is valid and showed that the anterior and PB posterior site-specific defects differ. Further, the present research paved the way for future research to demonstrate the UGH and PB role in the POP-Q system.

The limitations of the current study were the lack of access to subjects' medical records and one researcher's interpretation of the UGH and PB anatomy findings. Cadaveric UGH and PB dimensions did not correspond to the actual measurements in live subjects. Additionally, in this study on human corps, the functional anatomy of the urogenital hiatus and perineal body could not be determined. Furthermore, the anatomical dissection can only be executed in a prone position and POP-Q recommends examining a patient in a) the supine position; b) standing; c) patient straining.

Interpretations

The urogenital hiatus width and length can be enlarged by a direct detachment of the pubovaginalis muscle from the inferior pubic bone or indirect by the pubovisceral muscle or obturator internus muscle separation the arch tendinous fascial pelvis, Fig. 1B. When UGH enlarges, and it is not corrected, the surgical outcome for pelvic organ prolapse is unsatisfactory or failure [8]. Furthermore, the posterior compartment reconstruction does not improve surgical success when UGH is enlarged [24].

Conclusions

The POP-Q system does not adequately assess UGH and PB and needs revision or abandonment.

Declaration of Competing Interest

The authors declare that they have no known competing financial interests or personal relationships that could have appeared to influence the work reported in this paper.

Acknowledgments

The author is grateful to Prof. Dr. Pawel Krajewski for providing fresh adult human female cadavers and obtaining the study's protocol approval from the Bioethics Committee of the local university. The author also wishes to sincerely thank those who donated their bodies to science to perform anatomical research. Results from such a study can potentially improve patient care and increase humankind's overall knowledge. Therefore, these donors and their families deserve our highest gratitude.

Ethical statement

The Medical University Bioethics Committee approved the study's protocol before the investigation was commenced.

Funding

This work did not receive any funding

Author contributions

The author establishes the concept, designs the study's protocol, collects data, analyses and interprets data, and drafts the manuscript.

References

[1] Bump RC, Mattiasson A, Bø K, Brubaker LP, DeLancey JOL, Klarskov P, et al. The standardization of terminology of female pelvic organ prolapse and pelvic floor dysfunction. Am J Obstet Gynecol 1996;175(1):10–7.
[2] DeLancey JO, Hurd WW. Size of the urogenital hiatus in the levator ani muscles in normal women and women with pelvic organ prolapse. Obstet Gynecol 1998;91(3):364–8.
[3] Sammarco AG, Nandikanti L, Kobernik EK, Xie B, Jankowski A, Swenson CW, et al. Interactions among pelvic organ protrusion, levator ani descent, and hiatal enlargement in women with and without prolapse. Am J Obstet Gynecol 2017;217(5):614.e1–7. https://doi.org/10.1016/j.ajog.2017.07.007.

[4] Ghafar MA, Chesson RR, Velasco C, Slocum P, Winters JC. Size of urogenital hiatus as a potential risk factor for emptying disorders after pelvic prolapse repair. J Urol 2013;190(2):603–7.
[5] Henry MM, Parks AG, Swash M. The pelvic floor musculature in the descending perineum syndrome. Br J Surg 1982;69(8):470–2.
[6] Clark NA, Brincat CA, Yousuf AA, DeLancey JOL. Levator defects affect perineal position independently of prolapse status. Am J Obstet Gynecol 2010;203(6):595.e17–22.
[7] Macalister A. textbook of human anatomy: systemic and topographical. Including the embryology, histology and morphology of man. With special reference to the requirements of practical surgery and medicine. London, UK: Charles Griffin Co;1889; 366; available in the digital format: https://search.wellcomelibrary.org/iii/encore/record/C__Rb2106517?lang=eng Retrieved Dec 23, 2020.
[8] Wilson PM. Anchoring mechanisms of the ano-rectal region. I S Afr Med J 1967;41(43):1127–32.
[9] Oh C, Kark AE. Anatomy of the perineal body. Dis Col and Rect 1973;16(6):444–54.
[10] Wagenlehner FM, Santoro GA, Petros P. Live anatomy of the perineal body in patients with a third-degree rectocele. Colorectal Dis 2013;15(11):1416–22.
[11] Hakelius L. Reconstruction of the perineal body as treatment for anal incontinence. Br J Plast Surg 1979;32(3):245–52.
[12] Woodman PJ, Graney DO. Anatomy and physiology of the female perineal body with relevance to obstetrical injury and repair. Clin Anat 2002;15(5):321–34.
[13] Abedi P, Jamali S, Tadayon M, Parhizkar S, Mogharab F. Effectiveness of selective vaginal tightening on sexual function among reproductive-age women in Iran with vaginal laxity: a quasi-experimental study. J Obstet Res 2014;40(2):526–31.
[14] Larson KA, Yousuf A, Lewicky-Gaupp C, Fenner DE, DeLancey JOL. Perineal body anatomy in living women: 3-dimensional analysis using thin-slice magnetic resonance imaging. Am J Obstet Gynecol 2010;203(5):494.e15–21.
[15] Cunningham FG, Leveno KJ, Hauth JC at al. Williams Obstetrics 22nd edition. New York, U.S.A. McGraw-Hill Medical Publishing Division; 2005:21.
[16] Raz S. Atlas of transvaginal surgery. W.B. Saunders Company, Philadelphia, PA, USA, 2002, p33.
[17] Oelrich TM. Striated urogenital muscle in the female. Anat Rec 1983;205:223–32.
[18] Soga H, Nagata I, Murakami G, Yajima T, Takenaka A, Fujisawa M, et al. A histotopographic study of the perineal body in elderly women: the surgical applicability of novel histological findings. Int Urogynrcol J Pelvic Floor Dysfunct 2007;18(12):1423–30.
[19] Ostrzenski A, The A. first clinical classification of vaginal introital defects. Eur J Obstet Gynecol Reprod Biol 2011;159(2):449–52.
[20] Ostrzenski A. Anterior vaginal introitoplasty for an acquired sensation of wide vagina: a case report and new surgical intervention. J Reprod Med. 2014;59(5-6):327-329.
[21] Ostrzenski A. Modified posterior perineoplasty in women. J Reprod Med. 2015;60(3-4):109-116.
[22] Maldonado PA, Carrick KS, Montoya TI, Corton MM. Posterior vaginal compartment anatomy: implications for surgical repair. Female Pelvic Med Reconstr Surg 2020;26(12):751–7. https://doi.org/10.1097/SPV.0000000000000707.
[23] Zetterström JP, Mellgren A, Madoff RD, Kim GG, Wong WD. Perineal body measurement improves evaluation of anterior sphincter lesions during endoanal ultrasonography. Dis Colon Rectum 1998;41(6):705–13.
[24] Sutkin G, Zyczynski HM, Sridhar A, Jelovsek JE, Rardin CR, Mazloomdoost D, et al. Association between adjuvant posterior repair and success of native tissue apical suspension. Am J Obstet Gynecol 2020;222(2):161.e1–8. https://doi.org/10.1016/j.ajog.2019.08.024. Epub 2019 Aug 23.