

Selecting Aesthetic Gynecologic Procedures for Plastic Surgeons: A Review of Target Methodology

Adam Ostrzenski



Received: 1 September 2011 / Accepted: 17 November 2012
© Springer Science+Business Media New York and International Society of Aesthetic Plastic Surgery 2013

Abstract

Background The objective of this article was to assist cosmetic-plastic surgeons in selecting aesthetic cosmetic gynecologic-plastic surgical interventions.

Methods Target methodological analyses of pertinent evidence-based scientific papers and anecdotal information linked to surgical techniques for cosmetic-plastic female external genitalia were examined. A search of the existing literature from 1900 through June 2011 was performed by utilizing electronic and manual databases.

Results A total of 87 articles related to cosmetic-plastic gynecologic surgeries were identified in peer-review journals. Anecdotal information was identified in three sources (Barwujuk, *Obstet Gynecol J* 9(3):2178–2179, 2011; Benson, 5th annual congress on aesthetic vaginal surgery, Tucson, AZ, USA, November 14–15, 2010; Scheinberg, *Obstet Gynecol J* 9(3):2191, 2011). Among those articles on cosmetic-plastic gynecologic surgical technique that were reviewed, three articles met the criteria for evidence-based medicine level II, one article was level II-1 and two papers were level II-2. The remaining papers were classified as level III. The pertinent 25 papers met the inclusion criteria and were analyzed. There was no documentation on the safety and effectiveness of cosmetic-plastic gynecologic procedures in the scientific literature.

Conclusions All published surgical interventions are not suitable for a cosmetic-plastic practice. The absence of documentation on safety and effectiveness related to cosmetic-plastic gynecologic procedures prevents the establishment of a standard of practice. Traditional gynecologic surgical procedures cannot be labeled and used as cosmetic-plastic procedures, it is a deceptive practice. Obtaining legal trademarks on traditional gynecologic procedures and creating a business model that tries to control clinical-scientific knowledge dissemination is unethical.

Level of Evidence III This journal requires that authors assign a level of evidence to each article. For a full description of these Evidence-Based Medicine ratings, please refer to the Table of Contents or the online Instructions to Authors www.springer.com/00266.

Keywords Vaginal rejuvenation · Cosmetic gynecology · Labia minora labioplasty · Labia majora labioplasty · Clitoral hoodoplasty · Wide vagina · G-spotplasty · Defibulation

Introduction

External genitalia rejuvenations are surgical interventions performed on the skin and cosmetic and plastic surgeons (cosmetic-plastic) have been performing more of them than ever before. This growing involvement of cosmetic-plastic surgeons in aesthetic gynecology has created controversy about whether they are qualified to perform these surgeries on female external genital organs. Formally, cosmetic-plastic surgeons have been trained during their accredited residency programs to perform skin rejuvenation operations. Also, it is my conviction that the reconstructive cosmetic gynecology involving the posterior perineum, perineal body,

A. Ostrzenski (✉)
Institute of Gynecology, Inc, 7001 Central Ave.,
St. Petersburg, FL 33710, USA
e-mail: ao@baymedical.com

and perineal membrane can be performed by cosmetic-plastic surgeons with additional training since it constitutes a superficial group of muscles, fascia, and skin.

In 2010, Liao et al. [17] first assessed the scientific literature on labia minora labioplasty. In 2011, Ostrzenski [24] presented a scientific review of cosmetic-plastic gynecologic procedures related to all female external genitalia. Hailparn [10] reviewed and addressed the 1st International Cosmetic Gynecology and Cosmetology Congress in Istanbul, Turkey, April 2011, about the existing literature on cosmetic gynecology from 2007 until now and concluded that the cosmetic gynecologic field made significant progress. These publications documented the strengths, weaknesses, and the immediate need for clinical well-designed and executed scientific research [10, 17, 24] as well as the deceptive and unethical practice, teaching, and marketing of cosmetic gynecologic procedures such as Laser Vaginal Rejuvenation® (Institute of America, Beverly Hills, CA, USA) and Designer Laser Vaginoplasty® (Institute of America, Beverly Hills, CA, USA) which were established by ACOG and confirmed by others [3, 10, 11, 24, 30].

The objective of this article was to assist cosmetic-plastic surgeons in selecting aesthetic cosmetic gynecologic-plastic surgical interventions. Suggestions are based upon methodological examination of pertinent scientific papers and anecdotal information which were linked to surgical techniques in the cosmetic gynecology field.

Methods

An electronic search of the existing literature for relevant articles, including those from international congresses, from 1900 to May 2010 was performed. Medical Subject Headings (MeSH) and the terms labia minora labioplasty; labioplasty; minoroplasty; female labioplasty; labial hypertrophy; labial rejuvenation; reconstruction labioplasty; clitoral hoodoplasty; redundant clitoral prepuce; redundant clitoral prepuce reconstruction; clitoral frenuloplasty; hymenoplasty; revirgination; vaginal rejuvenation; dorsal perineal membrane reconstruction; urethrovaginal sphincter muscle reconstruction; vaginal introitus; vaginal introital reconstruction; laser vaginal rejuvenation® (Institute of America, Beverly Hills, CA, USA); designer laser vaginoplasty® (Institute of America, Beverly Hills, CA, USA); vaginoplasty; designer vaginoplasty; designer vaginal revirgination; designer vagina; cosmetic vaginal procedures; G-spotplasty; G-spot amplification®; deinfibulation; defibulation; wide vagina; smooth vagina; female genitalia; cosmetic gynecology; female genitalia plastic surgery; female cosmetic surgery; female genital surgery; cosmetic genital surgery; trans-sexual gender reassignment surgery; female genitalia congenital anomalies were

used to search the ISI Web of Science (including conference proceedings), 1950 PubMed, ACOGNET, ProQuest, OVID, Cochrane Collection, Lancet Online Collection, MDConsultant, New England Journal of Medicine, American College of Physicians Online Resources, Highwire Journal, EMBASE, SCOPUS, and Citation Index Reference. A manual search also was conducted. There were no limitations related to language or data. The authorship was unsealed. Because the published data were publicly available for this review, Institutional Review Board approval was not needed. The systematic review was conducted using the Cochrane Handbook for Systematic Reviews of Interventions, version 5.0.2 [14], which included criteria for considering scientific articles for inclusion, scrutiny of methodological quality, and processing of included studies. The evidence-based medicine level designation of analyzed articles was determined based upon the U.S. Preventive Services Task Force [6].

At the outset, the study was designed as a systematic review and later on was changed to a methodological evaluation due to insufficient scientific data to fulfill the requirements for the reporting system. Also, subjects' postoperative satisfaction could not be evaluated because no single scientific article was sufficiently designed to meet the rigorous scientific criteria for patient satisfaction which incorporates influence of demand characteristics, social pressure, degree of satisfaction, absence of regret, and cognitive dissonance (conflict and dilemma). In general, the existing literature in cosmetic-plastic gynecology that was related to evaluation of satisfaction was based upon surgical outcomes and not on the fundamental scientific rules of satisfaction evaluation.

Articles were selected and assigned to a specific procedure group and analysis was conducted on surgical methods and potential negative/positive aesthetic outcomes. Also, intraoperative and short- and long-term surgical complications were incorporated into this study.

Inclusion Criteria

Articles on external genital surgical interventions for cosmetic and medical reasons were identified in peer review medical journals in multiple languages and were included for analysis in this study. Scientific material from congresses were included and classified as anecdotal information. All evidence-based medicine level articles were included.

Exclusion Criteria

Vulvovaginal reconstruction for malignancy, female genital cutting, sex reassignment in transsexuals, congenital adrenal hyperplasia, gender identity disorders, hermaphrodites,

ambiguous genitalia, ventral approach for reductive clitoris, and pediatric cosmetic gynecology were excluded from this study. Also, articles on Laser Vaginal Rejuvenation® (Institute of America, Beverly Hills, CA, USA), Designer Laser Vaginoplasty® (Institute of America, Beverly Hills, CA, USA), and G-Spot Amplification® were excluded from this study because in September 2007 the American College of Obstetricians and Gynecologists (ACOG) established that these terms represent traditional gynecologic procedures and were labeled as cosmetic gynecologic surgical interventions. Additionally, ACOG expressed its concerns about an unethical and deceptive cosmetic-plastic gynecology practice under these legally trademarked terms [3].

Results

Altogether, 28 of the 87 articles that were found in peer review journals were selected for this study. Anecdotal information was identified in three sources. Among the reviewed articles on cosmetic-plastic gynecology, three articles met in evidence-based medicine level II, one article was II-1 and two were II-2. The remaining 25 scientific papers were classified as level III. There was lack of documentation on the safety and effectiveness of cosmetic-plastic gynecologic procedures in the scientific literature.

Labia Minora Labioplasty (LmL)

The search of the literature found 57 publications on labia minora labioplasty and a detailed analysis of these articles was presented by Ostrzenski in a previous report [20]. All of these reviewed articles met the criteria for level III evidence-based medicine (descriptive study and/or case reports) [14]. Eight surgical techniques applicable to LmL were established. All identified LmL techniques are presented chronologically as they were published.

LmL: Simple Labioplasty (Partial and Straightforward Amputation)

In 1976, Radman [28] first described labia minora labioplasty for medical indication by means of amputation, and in 1984, Hodgkinson and Hait [15] adopted this technique for aesthetic motives. Therefore, labia minora reduction by amputation is a traditional gynecologic procedure that was adopted for cosmetic-plastic use. A labia minora amputation also was called sculpted linear resection or “S” resection or Barbie’s cut. I suggest including a partial amputation (resection) technique in the cosmetic-plastic surgeon’s armamentarium. Labia minora partial amputation should be used infrequently in a very selective group

of patients and cannot be considered a one-size-fits-all procedure. Also, an LmL by partial amputation can be applied intraoperatively when another technique is not performed satisfactorily. A straightforward LmL technique should be avoided since it can lead to unintended superficial dyspareunia due to the incision being too close to the base of the labia minora (under 1 cm), and usually the clitoral prepuce appears too accentuated afterward creating unsatisfactory aesthetic outcomes.

LmL: Central V-Plasty

In 1998, Alter [1] developed and published a new method of the central V-plasty technique for LmL. This technique is very simple and reduces the labia minora’s size and preserves its natural edges and shape. The procedure was initially accepted by cosmetic-plastic surgeons with great enthusiasm. However, they learned that this surgical intervention disobeys a principal rule of cosmetic-plastic surgery because it creates a transverse visible scar on the labia minora (a vertical organ). In my opinion, an unsatisfactory aesthetic result disqualifies the central V-plasty for application in the cosmetic-plastic gynecologic field. In addition to the transverse visible scar, it has been reported that wrinkling at the base of the labia minora is often unavoidable when a large amount of tissue is removed [4]. Also, a scar may interfere with labial erectile function by separating the continuity of the labia’s erectile tissues.

LmL: W-Plasty

In 1998, Maas and Hage [18] described a running interdigitating W-shaped excision of the labia minora. This technique is an interlocking double V-plasty. Due to unacceptable visible scars, I do not include this procedure in my practice.

LmL: Inferior V-Plasty Reduction

In 2000, Rouzier et al. [29] described the inferior V-plasty. In this technique, upon determining the length of labia to be excised, the first Kocher clamp is placed at the base of the posterior labia minora. A second Kocher’s clamp is placed at a 90° angle. The posterior labial excision has to be carried out under the clamp and the upper labia excisions need to be executed above the clamp. A posterior labia excision under the clamp leaves crushed tissue created by the clamp. Also, such placement of the clamp will force the surgeon to perform an excision at the labia base surface. This creates a denuded lateral and posterior vaginal introitus; therefore, the aesthetic results of this procedure are not acceptable. The crushed tissue would interfere

with the healing process and predisposes to wound suture line separation. Indeed, wound separation was present in as high as 7 % of patients. Also, there was a high prevalence of superficial dyspareunia due to the very low posterior labia excision.

Negative aesthetic outcomes of the inferior V-plasty technique and the high prevalence of potential complications of this surgical intervention should preclude a cosmetic-plastic surgeon or any surgeon from including it in cosmetic-plastic gynecology practice. Also, this technique requires general anesthesia.

LmL: Deepithelialized Reductive Labioplasty

In 2000, Choi et al. [7] described a new method for aesthetic reduction of the labia minora. The operation was executed under local anesthesia. In this technique the lamina of the labia minora was removed bilaterally (deepithelialization). The free edge of the labia was approximated with the labia minora base. Such approximation will lead to folding the labia minora at the base, similar to “accordion” folding, making the labial base appearance unnaturally thick. This surgical method can be used in a select group of patients who have thin and minimally elongated but hypertrophied labia minora.

LmL: Nymphectomy with a 90° Z-Plasty

In 2004, the procedure of Giraldo et al. [9] was performed under local anesthesia. Individually designed templates were made from radiographic films, and two 90° Z-plasty shapes were marked on both sides of the labia. The 90° Z-plasty excision was made to reduce the size of the labia minora. This surgical intervention is not acceptable because it will produce three visible scars.

LmL: Inferior Wedge Resection and Superior Pedicle Flap Reconstruction

In 2006, Munhoz et al. [19] presented their new LmL surgical technique, which is executed with local anesthesia. The operation starts by determining two points. Point A is decided by identifying the most protruding aspect of the labia minora laterally. Point B is decided by bringing point A to the posterior labia minora without tension. The incision is initiated at point B and continued alongside and above the base of the labia minora. The incision stops at the corresponding level of the urethral meatus. The upper tip of the incision is connected in a wedge shape with point A and the wedge is excised. Interrupted stitches approximate the edges. The procedure is very simple and aesthetically pleasing. It works very well in cases in which the labial edges are not excessively thick, dark, and irregular. By all

means, this aesthetic surgical intervention is worthwhile to learn and should be included in the cosmetic gynecologic surgeon’s armamentarium.

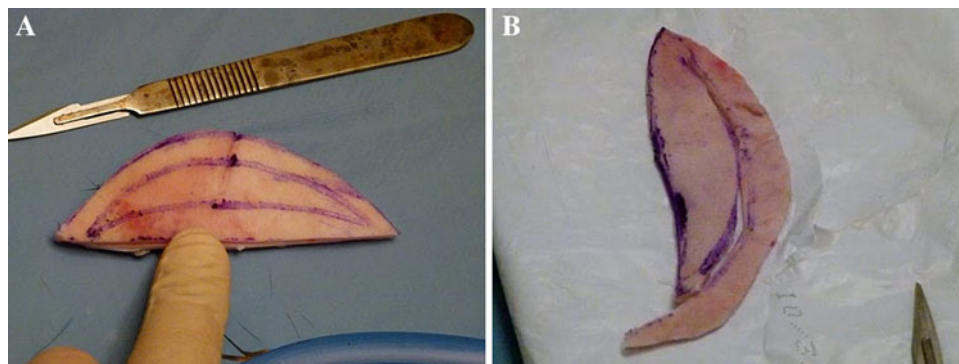
LmL: Ostrzenski’s Fenestration Labioplasty with Inferior Flap Transposition (OFL)

Between 2006 and 2010, I conducted a cosmetic-plastic gynecologic comprehensive study during which I developed the Ostrzenski fenestration labioplasty (OFL) with transposition of the distal labia technique [20], among other surgical techniques. This surgical intervention not only reduces the labia minora size but also can preserve natural edges, color, contour, and neurovascular bundle. The surgeon can predetermine shape, achieve bilateral symmetry, and hide incisions. Also, the OFL will restore or create the posterior border of the fossa navicularis. The operation is performed with local anesthesia but can also be performed with general or regional anesthesia. The procedure can be executed with or without neurovascular bundle preservation. After marking, the anterior labial lamina is separated from the connective tissue. The dissection continues until the embedded neurovascular bundle within the connective tissue is identified. The neurovascular bundle is preserved. The inferior flap of the labia is separated from the base and trimmed to the predetermined length. The surgical edges are approximated with single stitches without tension. OFL without neurovascular bundle preservation is initiated by marking incision sites in the “helmet-shape” delineation. The outlined part is excised and the edges are approximated. The transposition of the distal labial pedicle is executed and the new posterior fossa navicularis border is created (Fig. 1).

During the 1st International Cosmetic Gynecologic Congress in Istanbul, Turkey, Scheinberg [30, 31] presented his results from using the OFL technique, which he learned during a recognized CME workshop on Advanced Cosmetic Gynecology offered by the Institute of Gynecology, Inc. (www.cosmetic-gyn.com) and during a formal OR training-proctorship with me. He concluded that the aesthetic results of the OFL technique were outstanding and documented them with photos.

During the same congress, Barwijek [4] presented results of his comparative study of Alter’s central V-plasty technique versus OFL. He found that OFL yielded very impressive labial reductive aesthetic results when compared to Alter’s technique [1, 4, 20]. Barwijek learned the OFL technique during one of the Advanced Cosmetic Gynecology workshops offered by me. OFL is an anecdotal surgical intervention that offers very pleasing aesthetic surgical outcomes when a woman desires to keep the natural appearance of her labia minora free edges. This new technique has a lot of potential for a pleasing natural aesthetic appearance of the labia minora [4].

Fig. 1 Illustration of the Ostrzenski's fenestration labioplasty technique. **a** Incision sites were marked in the "helmet-shape." **b** The "helmet-shape" part was excised; the distal pedicle could be used, by the mode of transposition, to create the posterior fossa navicularis border



In summary, I practice, teach, and recommend the following selective surgical labioplasty techniques: Simple Labioplasty (a partial amputation), Deepithelialized Reductive Labioplasty, Inferior Wedge Resection and Superior Pedicle Flap Reconstruction, and Ostrzenski's Fenestration Labioplasty. In general, use of a one-size-fits-all procedure for cosmetic-plastic gynecology and expecting pleasing aesthetic results is unrealistic. I eliminated using and teaching surgical techniques that would not provide satisfactory aesthetic outcomes. I teach all eight labia minora labioplasty interventions (the eighth surgical technique describes the optional use of a laser) since there is no documentation that establishes the superiority of any one technique over another. Consequently, I leave the decision up to the woman and her practitioner to choose which surgical method will provide the best results to meet her needs.

Clitoral Hoodoplasty

In 1975, Kramarosky and Manriquez [16] first described restorative clitoral hoodoplasty for clitoral preputial phimosis. In this technique, the clitoral prepuce is separated from the clitoral glans using dull metallic instruments followed by trimming the clitoral prepuce. Since its introduction, this surgical method with different minor modifications has been used not only for medical but also for aesthetic reasons. The technique can cause significant potential complications, the most severe being neurosensory faculty loss which is manifested by clitoral numbness [5]. Due to the serious functional consequences of clitoral numbness, this method should be avoided.

In 2008, Alter [2] described a clitoral hoodoplasty by extension of central wedge resection. This procedure leaves two visible scars on the middle-lateral aspect of the clitoral prepuce. This is not only an aesthetic concern but also a functional one since the scars will not contain erectile tissue. So, for both aesthetic and functional reasons, this surgical technique should be avoided.

Between 2006 and 2010, I conducted the clinical study that helped me to develop a new clitoral hoodoplasty

classification scheme. This scheme is very useful for a practitioner. Clitoral preputial characteristics were used to establish the new classifications: (1) *Occluded* Clitoral Prepuce, (2) *Hypertrophic-Gaping* Clitoral Prepuce, and (3) *Asymmetrical Subdermal Hypertrophy*. Each category of clitoral characteristics requires a different and specific surgical intervention. The following surgical interventions for clitoral hoodoplasty have been developed and based upon this classification scheme: (1) hydrodissection with reverse V-plasty was suggested for occluded clitoral prepuce [21], (2) modified hydrodissection with reverse V-plasty was recommended for hypertrophic-gaping clitoral prepuce [22], and (3) subepithelial reduction was the option for asymmetrical subdermal hypertrophy [25].

In 2010, I described a new surgical intervention called hydrodissection with reverse V-plasty technique for restorative clitoral hoodoplasty [21]. The concept was based on restoring both the obliterated opening of the clitoral prepuce and the thinning and vanishing clitoral prepuce without using any metallic instruments so as to avoid clitoral nerve injury (Figs. 2 and 3). This surgical method was modified and used for reductive clitoral hoodoplasty [22]. In the modified technique, no preputial surgical incision is needed to gain access between the inner surface of the clitoral prepuce and the clitoral body. The hydrodissection process is applied under direct visualization to divide adhesions and to eradicate agglutination between the inner surface of the clitoral prepuce and the clitoris and to remove smegma and debris. The excessive clitoral preputial tissue is excised in reverse V-plasty mode. The suture line is hidden in the newly created clitoral preputial opening, with the clitoral glans being exposed between 3 mm and 5 mm [23]. The modified hydrodissection technique is simple, easy to learn, and has very natural and pleasing aesthetic outcomes. The hydrodissection with reverse V-plasty method for reductive hoodoplasty is recommended for cosmetic-plastic surgeons (Figs. 2 and 3).

In 2010, I developed a new surgical technique called the subepithelial clitoral hoodoplasty (SECH) [22]. This

Fig. 2 Ostrzenski's hydrodissection with reverse V-plasty technique. **a** Buried clitoris under the skin. **b** Hydrodissection completed and the reverse V-plasty began

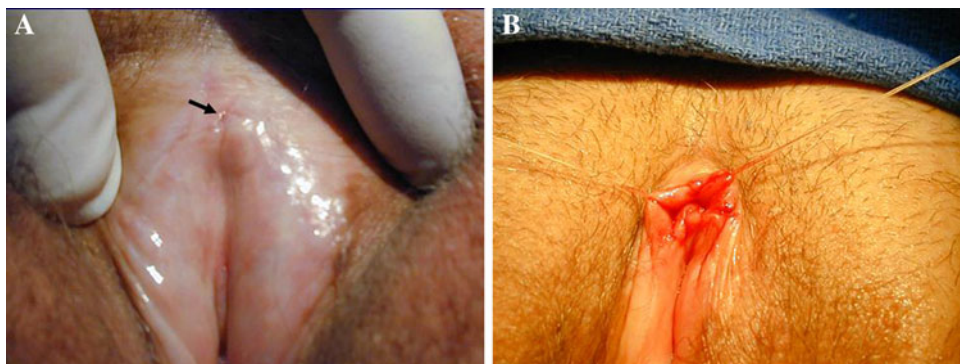


Fig. 3 Ostrzenski's clitoral hoodoplasty by hydrodissection with reverse V-plasty method. **a** Shortly after completion of the procedure. **b** Six months after surgical intervention

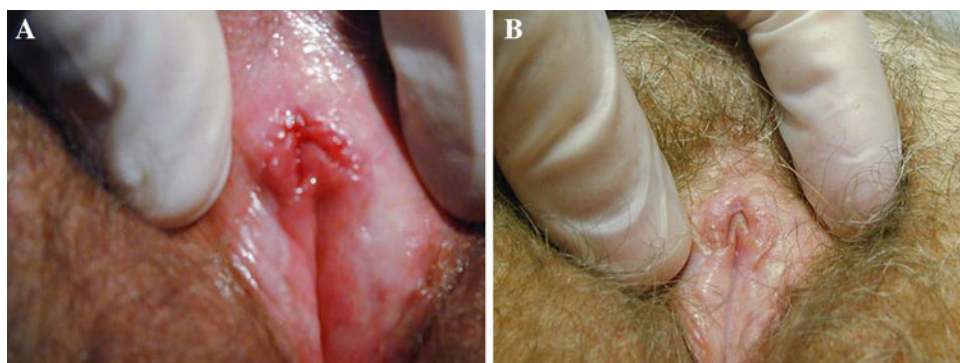
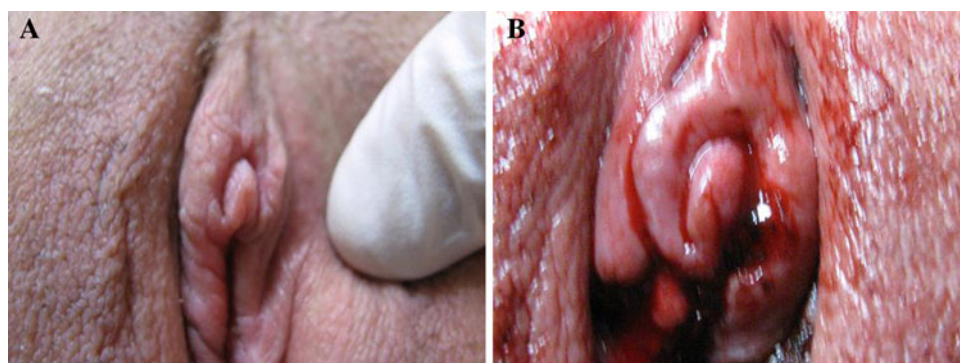


Fig. 4 Ostrzenski's subepithelial clitoral hoodoplasty. **a** Asymmetrical subepithelial preputial hypertrophy. **b** Subepithelial clitoral preputial resection was completed. Incisional edges came together without stretching or tension before suturing



surgical method is very useful when the clitoral prepuce has uneven thickness. Reductive clitoral hoodoplasty itself is not enough to accomplish satisfactory aesthetic results. The operation can be combined, and often is, with a modified hydrodissection with reverse V-plasty for reductive clitoral hoodoplasty [21]. Also, SECH can be performed as a single procedure when the length of the clitoral prepuce does not require reduction. The concept of this surgical intervention is to resect the subepithelial hypertrophied tissues to create bilateral symmetrical thickness of the clitoral prepuce. This surgical intervention should be applied when asymmetrical thickness of the clitoral prepuce is identified [22]. The procedure is simple and easy to learn (Fig. 4).

Clitoral Frenuloplasty

Clitoral frenuloplasty was developed by me during my comprehensive cosmetic-plastic gynecologic clinical study. A surgery for aesthetic reasons is usually needed when the clitoral frenulum is enlarged, asymmetric, or both. Sometimes it also requires transposition of the frenulum to the posterior clitoral glans. This procedure is almost always performed in association with a modified reductive clitoral hoodoplasty or subepithelial clitoral hoodoplasty [22]. Caution must be exercised while performing a clitoral frenuloplasty because the bulboclitoral region, which is a highly neurosensitive area, lies between and posterior to both frenula just under the epithelium. The bulboclitoral

region incorporates the clitoral root and the commissure of the vestibular bulbs, also known as the “pars intermedia.” It is much safer to reduce the clitoral frenulum by slicing the outside part of it. In many instances, clitoral frenuloplasty is necessary to achieve aesthetically desirable results.

Labia Majora Labioplasty

In 2007, Felicio [8] first described the labia majora labioplasty technique. A predetermined amount of labia majora skin with the fat layer is removed. The suture line is of interrupted absorbable stitches and is hidden in the creases between the bases of the labia minora and the labia majora.

Labiopexy of the labia majora is my new concept. In the Ostrzenski Labiopexy technique, the skin is dissected from the fat tissue sac. Colles’ fascia under the fat capsule is identified and excised. The excision of Colles’ fascia does not correspond to the trimmed amount of skin because they are different sizes. Thus, the skin is stretched over the

larger piece of fat tissue and provides a more natural and younger appearance without wrinkles. The reduced Colles fascia provides the base for the fat tissue to be stabilized. After the Ostrzenski Labiopexy, the newly transformed labia majora looks more youthful and taut. This surgical method is simple to learn for cosmetic-plastic surgeons and yields a very pleasing aesthetic look (Figs. 5, 6).

There is anecdotal information that suggests that horizontal labia majora labioplasty is an acceptable procedure for labia majora labioplasty. I have never performed this type of surgery so my opinion is theoretical. A horizontal excision will leave a horizontal scar on the labia majora. Such an approach is not cosmetically pleasing as it will create a transverse scar on a vertical organ (the labia majora).

Also, I use a one-touch autologous fat transfer technique for labia majora augmentation. In this technique the fat tissues are harvested with a cannula connected to a syringe and then transferred immediately to the predetermined location(s) on the labia majora. Aesthetically, this technique is very pleasing; however, it lasts a relatively short

Fig. 5 Ostrzenski’s labiopexy (labia majora labioplasty). **a** The labia majora shows ptosis, sagging, wrinkling, depressions, and dimpling areas. **b** The skin incision was carried out until Colles’ fascia was identified and partially excised in an elliptical shape to stretch and to increase the tension of the lax Colles’ fascia, which is the foundation on which the encapsulated fat tissue rests

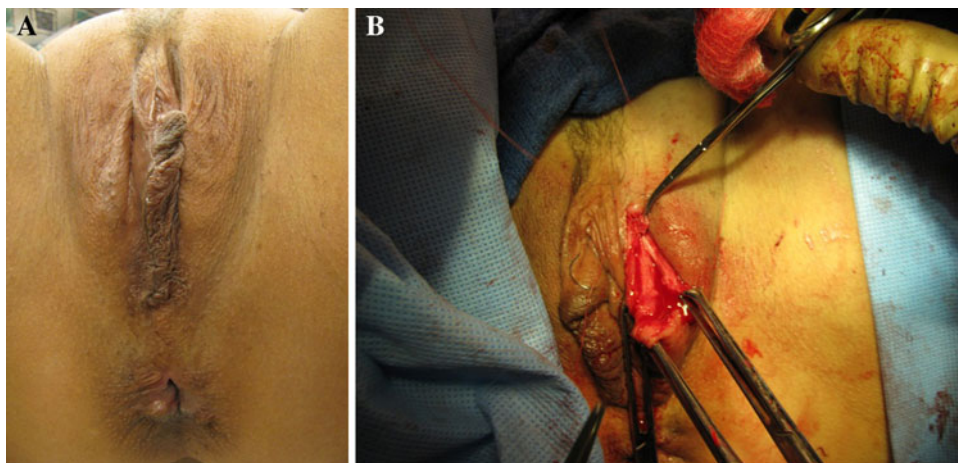
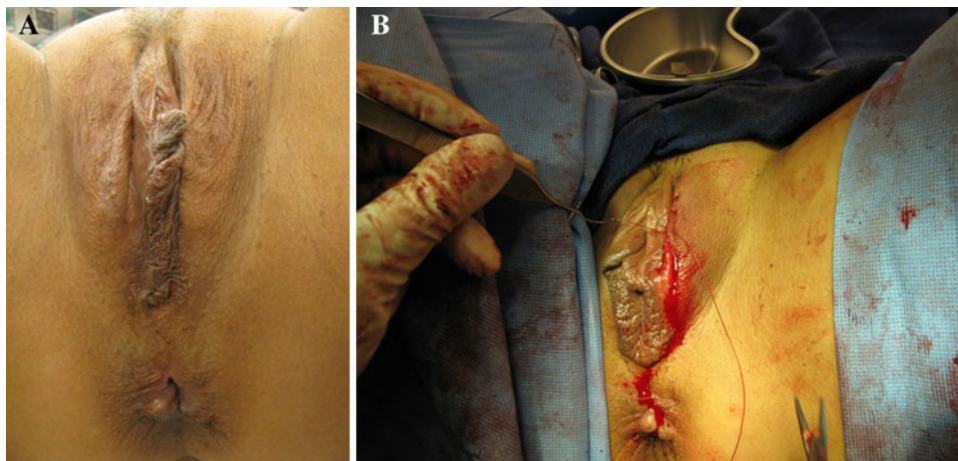


Fig. 6 Ostrzenski’s labiopexy. **a** The labia majora shows ptosis, sagging, wrinkling, depressions, and dimpling areas. **b** Completed; ptosis, sagging, wrinkling, depressions, and dimpling were eradicated; skin suturing was in progress



time. Three consecutive transfers of the fat tissue every 3 months provides an improved outcome for a much longer duration.

Hymenoplasty (Revirgination)

The hymeneal membrane's medical function has not been determined. However, its social, cultural, and religious meanings are very powerful and harbor significant consequences. Analyzing the social, cultural, and religious aspects of a hymenoplasty should be taken into account during the decision-making process.

I define revirgination (hymenoplasty) as restoration of the hymeneal membrane's gross anatomical integrity. In my opinion, revirgination is an unfortunate term since virginity cannot be re-established; I suggest using the term hymenoplasty instead. A hymenoplasty is performed for one of three reasons: (1) after rape or incest, (2) the reversal of female cutting, and (3) to eliminate signs of a woman's history of sexual vaginal activities. Also, there is a new trend in western multicultural societies to establish "secondary" virginity to prevent sexually transmitted diseases, prevent pregnancy, and maintain sexual abstinence for religious reasons, and because of changing personal views on premarital sexual activities.

There is no surgical description of hymenoplasty presented in the clinical-scientific literature; therefore, the safety and effectiveness of this procedure is not known. I have performed hymenoplasty by scarification of edges and by approximation of hymeneal membrane tags with single, interrupted, short-lasting absorbable stiches.

Vaginal Rejuvenation

In regard to the terms Laser Vaginal Rejuvenation[®] (LVR[®], Institute of America, Beverly Hills, CA, USA) and Designer Laser Vaginoplasty[®] (DLV[®], Institute of America, Beverly Hills, CA, USA), the description of the procedures, their standardization, and exact meaning of these terms have never been described. It has been established that LVR[®] is simply a traditional colpoperineoplasty procedure and DLV[®] is a traditional partial labioplasty with or without clitoral hoodoplasty [3, 24, 30]. Also, ACOG classified these procedures as traditional gynecologic procedures under the new terms [3]. Therefore, in my opinion, practicing traditional gynecologic procedures under new cosmetic labels with legal trademarks and charging a patient a higher fee for cosmetic procedures is deceptive and unethical. "Vaginal rejuvenation," the term introduced and used by ACOG, has become a very powerful marketing tool and is well recognized by women [3]. For this reason, vaginal rejuvenation has been widely used as a marketing instrument of cosmetic-plastic gynecology.

Between 2006 and 2010, I conducted a clinical study on acquired sensation of the wide/smooth vagina. The study's results documented that a wide/smooth vagina is the primary reason for women to request vaginal rejuvenation. Also, the study established that there are different causes of wide/smooth vagina and a one-size-fits-all procedure could not correct all the underlying causes. It is essential to establish the cause of the acquired sensation of a wide/smooth vagina and select one of the vaginal rejuvenation surgical interventions to correct the specific anatomical abnormality [25]. The clinical trial outcomes assisted in developing seven new vaginal rejuvenation (VR) surgical techniques, including Vaginal Rugation Rejuvenation, Anterior Vaginal Introitoplasty, Lateral Vaginal Introitoplasty, Posterior Vaginal Introitoplasty, Perineal Membrane Reconstruction, Pubocervical Fascia Reconstruction with Posterior Vaginal Wall Resection, and Hymeneal Plate Reconstruction (not a form of hymenoplasty). Ostrzenski's Vaginal Rejuvenation classification and Vaginal Rugation Rejuvenation have been published in peer review journals [26]. Hailparn presented Ostrzenski's Vaginal Rejuvenation classification during the same congress in Istanbul and emphasized the positive clinical role that this classification can play in the practice of cosmetic-plastic gynecology [12].

G-Spotplasty

In 2009, study results were presented in which the G-spot was identified in 82.3 % of the study participants. Anatomically, the G-spot was detected in 65.9 % as two small flaccid balloon-like masses on either side of the urethra and were named "sexual bodies of the G-spot," and histological documentation of the G-spot occurred in 47.4 %. Histological composition consists of the epithelial, glandular, and erectile tissue [32]. This notion has never been contested or confirmed in either clinical surgical settings or cadaver dissections. However, it does appear that Skeen's ducts were interpreted as the G-spot anatomic structure. In September 2011, I documented the existence of the G-spot anatomy [27].

Information on the G-spotplasty surgical technique that I developed is still anecdotal because it has not yet been published in any peer review journals. The G-spotplasty is a simple surgical technique in which pubocervical fascia tension is created by partial excision of the fascia [23]. I perform it in cases associated with a wide middle vagina; details are presented in a separate article [25].

G-spot injection with collagen or G-Spot Amplification[®] has been popularized but the procedure has never been published on in peer review journals; therefore, it is in the anecdotal information category. The G-Spot Amplification[®] technique, however, can be used only by those

physicians who participate in the course offered by the Laser Vaginal Rejuvenation Institute of America (Institute), and a legal trademark imposed by the Institute effectively prohibits other practitioners from incorporating this method into their practice [11, 30]. Practitioners should exercise caution and not use the term G-Spot Amplification[®] to avoid legal consequences.

I introduced the autologous fat transfer technique for a G-spotplasty. This method falls into the anecdotal information category. Contrary to the trademark situation created by the Institute, my terms “G-Spotplasty” and “G-Spotplasty with Fat Transfer” can be used without fear of legal prosecution, since my terminologies are not under any legal restriction and I do not intend to secure the terms with a legal trademark. During the 1st International Congress of Cosmetic Gynecology, Hailparn presented the G-spot surgical augmentation technique [13].

Discussion

A woman and only a woman would know about being aesthetically dissatisfied with the appearance of her external genitalia and a practitioner should not superimpose his/her own aesthetic views upon women. In this study, I tried to expand the cosmetic-plastic surgeon’s knowledge related to the gynecologic field, because more women have been looking for cosmetic-plastic gynecologic services and cosmetic-plastic surgeons have been offering these treatments.

In view of the deceptive and unethical teaching of Laser Vaginal Rejuvenation Institute of America[®] (Beverly Hills, CA, USA), Designer Laser Vaginoplasty[®], and G-spot Amplification[®] offered by the Laser Vaginal Rejuvenation Institute of America, it is imperative for cosmetic-plastic surgeons to avoid learning, teaching, and marketing deceptive practices. The doctors who participated in the deceptive teaching of LVR[®] and DLV[®] offered by the Institute had a contractual obligation to keep quiet about these deceptive and unethical procedures because the Institute required a confidential agreement; this is why deceptive and unethical practice, teaching, and marketing prevailed for so long [10]. In 2007, the American College of Obstetricians and Gynecologists (ACOG) disclosed the deceptive and unethical practice of mislabeling traditional gynecologic procedures as cosmetic-plastic ones [3]. The ACOG Committee Opinion determined that “It is deceptive to give the impression that vaginal rejuvenation, designer vaginoplasty, revirgination, G-spot amplification, or any such procedures are accepted and routine surgical procedures” [3]. Indeed, the marketing literature leaves the impression that LVR[®] and DLV[®] and G-Spot Amplification[®] procedures are accepted and routine. Also, the ACOG Opinion supported the labia minora labioplasty but it did not

specify which technique it supported. In its document, ACOG stipulated that labia minora labioplasty can be performed for “...treatment for labia hypertrophy or asymmetrical labial growth secondary to congenital conditions, chronic irritation, or excessive androgenic hormones.” ACOG’s recommendation is to perform defibulation (deinfibulation) and referred to it as a cosmetic gynecologic procedure [3].

Conclusions

This study’s results establish that (1) the standardization of cosmetic-plastic gynecologic procedures cannot be suggested due to the absence of scientific-clinical data related to the safety and efficacy of the procedures. (2) Rudimentary scientific-clinical articles are available. (3) Traditional gynecologic surgical procedures cannot be labeled as cosmetic procedures because it is a deceptive form of practice and marketing. (4) Creating medical terminology trademarks and establishing a business model that tries to control clinical-scientific knowledge dissemination is unethical. (5) ACOG provides guidelines for practitioners and protects physicians and women against deceptive and unethical practice, teaching, and marketing of cosmetic gynecology. (6) Practicing cosmetic-plastic gynecology is possible within ACOG’s recommendations.

Disclosures The author has no conflicts of interest or financial ties to disclose.

References

1. Alter GJ (1998) A new technique for aesthetic labia minora reduction. *Ann Plast Surg* 40:287–290
2. Alter GJ (2008) Aesthetic labia minora and clitoral hood reduction using extended central wedge resection. *Plast Reconstr Surg* 122(6):1780–1789
3. American College of Obstetricians and Gynecologists (2007) Vaginal “rejuvenation” and cosmetic vaginal procedures, ACOG Committee Opinion No. 378. *Obstet Gynecol* 110:737–738. Available at http://www.acog.org/Resources_And_Publications/Committee_Opinions/Committee_on_Gynecologic_Practice/Vaginal_Rejuvenation_and_Cosmetic_Vaginal_Procedures
4. Barwijuk AJ (2011) A comparison of Ostrzenski’s technique of fenestration labioplasty with Alter’s v-plasty. In: 1st international cosmetology and cosmetic gynecology congress, Istanbul, Turkey, April 28–30, 2011. *Obstet Gynecol J* 9(3):2178–2179
5. Benson R (2010) Clitoral hood management in AVS. In: 5th annual congress on aesthetic vaginal surgery, Tucson, AZ, USA, November 14–15, 2010
6. Berg AO, Allan JD (2001) Introducing the third U.S. preventive services task force. *Am J Prev Med* 20(3 Suppl):3–4
7. Choi HY, Kim KT (2000) A new method for aesthetic reduction of labia minor (the de-epithelialized reduction labioplasty). *Plast Reconstr Surg* 105:419–422
8. Felicio Y (2007) Labial surgery. *Aesthet Surg J* 27:322–328

9. Giraldo F, González C, de Haro F (2004) Central wedge nym-
psectomy with 90-degree z-plasty for aesthetic reduction of the
labia minora. *Plast Reconstr Surg* 13:1820–1825
10. Hailparn TR (2011) Cosmetic gynecology publications from
2007 to now: a scientific appraisal. In: 1st international cosme-
tology and cosmetic gynecology congress, Istanbul, Turkey, April
28–30, 2011. *Obstet Gynecol J* 9(3):2181
11. Hailparn TR (2011) Practicing cosmetic gynecology within the
scope of ACOG recommendations. In: 1st international cosme-
tology and cosmetic gynecology congress, Istanbul, Turkey, April
28–30, 2011. *Obstet Gynecol J* 9(3):2181
12. Hailparn TR (2011) Vaginal rejuvenation: Ostrzenski's classi-
fication. In: 1st International cosmetology and cosmetic gyneco-
logy congress, Istanbul, Turkey, April 28–30, 2011. *Obstet
Gynecol J* 9(3):2181–2182
13. Hailparn TR (2011) G-spot augmentation: Ostrzenski's tech-
nique. In: International cosmetology and cosmetic gynecology
congress, Istanbul, Turkey, April 28–30, 2011. *Obstet Gynecol J*
9(3):2179
14. Higgins J, Green S (eds) (2008) *Cochrane handbook for sys-
tematic reviews of interventions*. Wiley, New York
15. Hodgkinson DJ, Hait G (1984) Aesthetic vaginal labioplasty.
Plast Reconstr Surg 74:414–416
16. Kramarosky C, Manriquez C (1975) Phimosis of the clitoris. *Rev
Chil Obstet Ginecol* 40:304–309
17. Liao LM, Michala L, Creighton SM (2010) Labial surgery for
well women: a review of the literature. *BJOG* 117:20–25
18. Maas SM, Hage JJ (1998) Re: aesthetic labia minora reduction.
Ann Plast Surg 41(2):685–686
19. Munhoz AM, Filassi JR, Ricci MD, Aldrighi C et al (2006)
Aesthetic labia minora reconstruction with inferior wedge
resection and superior pedicle flap reconstruction. *Plast Reconstr
Surg* 118:1237–1247
20. Ostrzenski A (2010) Fenestration labioplasty. In: 3rd world
congress on cosmetic vaginal surgery. American Academy of
Cosmetic Surgery, Orlando, FL, USA, January 26–31, 2010
21. Ostrzenski A (2010) A new, hydrodissection with reverse
v-plasty technique for the buried clitoris associated with lichen
sclerosis. *J Gynecol Surg* 26(1):41–48
22. Ostrzenski A (2010) Clitoral hoodoplasty. In: The 3rd global
congress on vaginal surgery of the international society of cos-
metogynecology, Las Vegas, NV, USA, September 23–25, 2010
23. Ostrzenski A (2010) Ostrzenski's G-spot Augmentation. In: 3rd
world congress on cosmetic vaginal surgery. American Academy
of Cosmetic Surgery, Orlando, FL, USA, January 26–31, 2010
24. Ostrzenski A (2011) Cosmetic gynecology in the view of evi-
dence-based medicine and ACOG recommendation: a review.
Arch Gynecol Obstet 284:617–630
25. Ostrzenski A (2011) An acquired sensation of wide/smooth
vagina: a new classification. *Eur J Obstet Gynecol Reprod Biol*
158(1):97–100
26. Ostrzenski A (2012) Vaginal rugation rejuvenation (restoration):
a new surgical technique for an acquired sensation of wide/
smooth vagina. *Obstet Gynecol Invest* 73(1):48–52
27. Ostrzenski A (2012) G-spot anatomy: a new discovery. *J Sex
Med* 9(5):1355–1359
28. Radman HM (1976) Hypertrophy of labia minora. *Obstet
Gynecol* 48(1 Suppl):78S–79S
29. Rouzier R, Louis-Sylvestre C, Paniel BJ, Haddad B (2000)
Hypertrophy of labia minora: experience with 163 reductions.
Am J Obstet Gynecol 182(1 Pt 1):35–40
30. Scheinberg MN (2011) Deceptive and unethical practice of cos-
metic gynecology. In: 1st international cosmetology and cosmetic
gynecology congress, Istanbul, Turkey, April 28–30, 2011.
Obstet Gynecol J 9(3):2191
31. Scheinberg MN (2011) Fenestration labioplasty: Ostrzenski's
technique. In: International cosmetology and cosmetic gyneco-
logy congress, Istanbul, Turkey, April 28–30, 2011. *Obstet
Gynecol J* 9(3):2191
32. Thabet SM (2009) Reality of the G-spot and its relation to female
circumcision and vaginal surgery. *J Obstet Gynaecol Res*
35(5):967–973