

Clitoral Prepucioplasty with Anterior Commissure Transposition

A Case Report and Description of a New, Minimally Invasive Surgical Technique

Adam Ostrzenski, M.D., Ph.D.

BACKGROUND: Clitoral prepucioplasty is a new surgical intervention for clitoral prepuce reconstruction. This procedure has not been described previously in the literature.

CASE: A 21-year-old, Caucasian woman, G₀P₀, presented with aesthetic concerns about her external genital anatomy, particularly the area surrounding the clitoral prepuce, which had significant excess folds of tissue on both sides. She underwent a new surgical procedure: clitoral prepucioplasty with anterior commissure transposition. The redundant clitoral prepuce reconstruction with anterior commissure was performed under local anesthesia. Postoperatively, she gave an account of no feelings of regret about having the operation, and her negative emotional-social feelings about her anatomic aberrations, clitoral area unattractiveness, sexual undesirability, embarrassment during sexual contacts, very low self-perceived body image, and decreased quality of intimate and social life had subsided. No intraoperative or postoperative complications were observed.

CONCLUSION: The redundant clitoral prepuce reconstruction was easy to perform and resulted in aesthetical-

ly pleasing outcomes, improved quality of life, improved self-perceived body image, and increased sexual desire and frequency. (J Reprod Med 2015;60:178–182)

[T]his surgical technique ... was easy to execute and ... had very pleasing aesthetic outcomes.

Keywords: clitoral hoodoplasty, clitoral prepuce reconstruction, clitoral prepucial redundoplasty, cosmetic genital surgery prepucioplasty, cosmetic gynecology, labia minora, labia minora labioplasty, redundant clitoral prepuce.

In light of recent clinical studies, it has been recognized that self-perceived body image is an important component of a person's quality of life. A woman's self-perceived body image of her genital anatomy can negatively affect female sexual function.¹⁻³ Surgical intervention can improve a woman's external genital appearance and, thereby, improve her self-perceived body image of genital anatomy. The hypothesis was formed that redundant clitoral prepuce can negatively influence a female's self-perceived body image perception, decrease quality of life, and decrease sexual function.

Dr. Ostrzenski was Professor, Department of Gynecology and Obstetrics, and Director, Division of Operative Gynecology, Howard University, Washington, D.C. (Ret.), and currently is Director, Institute of Gynecology, Inc., St. Petersburg, Florida.

Address correspondence to: Adam Ostrzenski, M.D., Ph.D., Institute of Gynecology, Inc., 7001 Central Avenue, St. Petersburg, FL 33710 (ao@baymedical.com).

Financial Disclosure: The author has no connection to any companies or products mentioned in this article.

The objective was to develop and describe a new surgical intervention for rectifying clitoral prepuce anatomic anomalies, to establish this surgical technique applicability, to evaluate aesthetic surgical outcomes, and to observe how this operation would affect this particular patient's quality of life and self-perceived body image and therefore her sexual life.

An electronic and manual search for the existing literature (from 1900 to May 2010) on this topic was carried out. Using Medical Subject Headings (MeSH) and the keywords *cosmetic gynecology, clitoral redundant prepuce, reconstruction labioplasty, female genital surgery, cosmetic genital surgery, labia minora labioplasty, labioplasty, vaginal rejuvenation, female genitalia, labial hypertrophy, vaginoplasty, designer vaginoplasty, and designer vagina*, which were selected and used in a search on ISI Web of Science (including conference proceedings), 1950 PubMed, ACOGNET, ProQuest, OVID, Cochrane Collection, the Lancet Online Collection, MDConsultant, New England Journal of Medicine, American College of Physician Online Resources, Highwire Journal, and Citation Index Reference.

Case Report

A 21-year-old, Caucasian, G₀P₀, sexually active college student presented with aesthetic concerns about her external genital anatomy, particularly the area surrounding the clitoral prepuce, which had significant excess folds of tissue on both sides. Also, she expressed her discontent with the labia minora being aesthetically unattractive, too large, and asymmetric, causing discomfort during sexual intercourse as well as embarrassment. However, she did not want to subject herself to 2 corrective procedures at the same time. She had experienced derogatory comments about the clitoral prepuce looking unnatural from her sexual partners in the past, although her recent sexual partner had never made any negative remarks about her unnatural genital anatomy. Moreover, she wanted to assess the surgical outcome of the redundant clitoral prepuce reconstruction before proceeding with the additional procedure. On physical examination the clitoral prepuce revealed its distal part being bent, and the part covering the clitoral glans was abnormally "looking up" (Figure 1). On the right side of the clitoral prepuce, 3 identifiable skin pleats were noted which were compressing, elevating, and shifting the clitoral prepuce to the left (Figure 1). On the left side only 1 redundant clitoral prepuce

skin pleat was present (Figure 1). The redundant clitoral prepucial skin folds were not symmetrically attached to the proximal clitoral prepuce, with the right side being fixed higher just under the anterior commissure. Bilaterally the pleats resembled the adjacent skin more than the clitoral prepuce. Also, the clitoral prepuce was wider at the attachment to the anterior commissure than would be expected (Figure 1). Superficial and deep palpation found the right side much thicker, deeper, wider, and firmer than the left side, and no palpable mass was identified. Additionally, on the right side the redundant prepucial tissue intimately compressed the clitoral body, whereas the left side did not. An ultrasound with a 3.5 MHz transducer was performed and verified clinical findings.

At the first interview the patient reported her feelings of (1) fear of sexual incompatibility due to clitoral prepuce anatomic aberrations, (2) unattractive clitoral area, (3) sexual undesirability, (4) feeling different because of her external genital anatomy, (5) decreased openness toward sexual interactions (sexual phobia and anxiety), (6) embarrassment during sexual contacts, (7) very low self-perceived body image, and (8) decreased quality of intimate and social life interactions and desire for meaningful changes in her sexual life. Based upon this history she was advised to keep a diary for the period of 3 months before surgery and for 6 months after her surgical treatment on each parameter reported above. Additionally, after surgery she was asked to record her feelings of regret related to having the operation of redundant clitoral prepuce reconstruction with the anterior commissure reposition. Her self-comparison of the degree of satisfaction with the operation on the redundant clitoral prepuce before and after redundant clitoral prepuce reconstruction was measured on a scale of 0–10 (0–3, dissatisfaction with the aesthetic look; 3–6, minimal satisfaction; and 7–10, maximum satisfaction).

Surgical Technique

The patient was advised that this surgical intervention was a new surgical technique and could not be considered as a routine or accepted operation. No promises were made that this procedure could enhance sexual gratification. Written informed consent, within the standard delineated by the American College of Obstetricians and Gynecologists, was signed by both the patient and a witness.⁴ The redundant clitoral prepuce reconstruction with

anterior commissure was performed under local anesthesia without conscious sedation.

A thick layer of lidocaine-prilocaine (2.5%/2.5%)

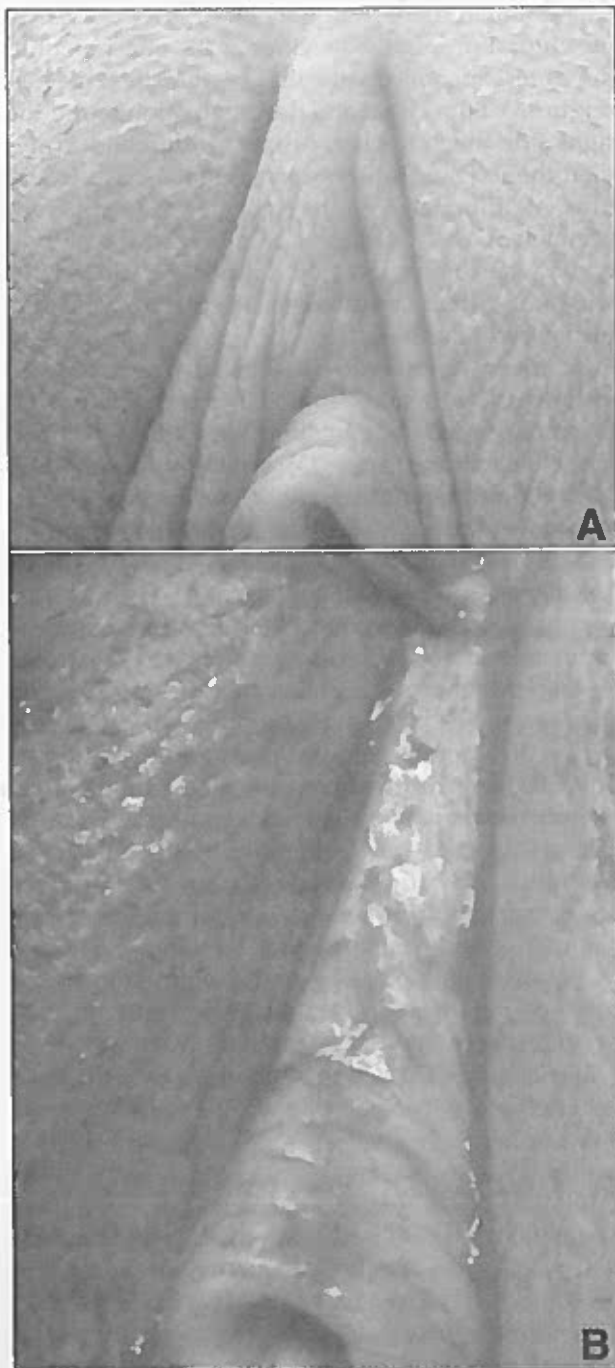


Figure 1 (A) Multiple redundant clitoral prepuce skin pleats, which caused compression on the clitoral prepuce and elevation of the distal part of the clitoral prepuce. (B) A cold knife excision of redundant clitoral prepuce was executed bilaterally.

cream was applied to the clitoral prepuce areas, including the intralabial creases and the immediate adjacent areas of the labia majora bilaterally; the region was covered with sterile gauze for 1 hour before surgery. The last 30 minutes before the procedure an ice pack was added to this area. Upon removing the ice pack, the anesthetic cream was wiped off and the operative field was prepped with Betadine solution. At the halfway point between the posterior commissure and the upper part of the anus, in the middle of the ischiopubic ramus and just under the superficial transverse perineal muscle, 5–10 mL of plain 1% lidocaine was injected with a 27 G \times 1/2-inch needle and 10 cc syringes (Terumo, Elkton, Maryland) into each side for local anesthesia. The superficial part of the deep branch of the perineal nerve and the posterior labial nerves were infiltrated with 1 injection. The distal part of the anterior labial branch of the ilioinguinal nerve, the distal part of the perineal branch of the posterior femoral cutaneous nerve, and the distal part of the dorsal clitoral nerve were infiltrated with 1% lidocaine at the halfway point between the insertion of the clitoral frenulum and the inguinal crease.

Symmetrically and bilaterally, the margins of the clitoral prepuce excisions were outlined. The de novo anterior commissure location, symmetry, and natural contour were determined. An incision was made with a No. 15 surgical blade. The predetermined volume (length and depth) of the redundant clitoral prepuce tissue was surgically removed with preservation of the main part of the clitoral prepuce covering the clitoral glans and the body (Figure 2). Meticulous hemostasis was accomplished. The squeezable rubber ball on a bulb syringe was filled with warm (body temperature) saline solution and was used for irrigation throughout the procedure to avoid the rubbing effect of surgical sponges. Once the pleats were excised bilaterally, the clitoral prepuce proximal part was transplanted to the tissue nest of de novo-created anterior commissure and sutured by applying a single type of suture with PDS 4-0. The incision edges were approximated in a subcuticular manner without any tension with PDS 4-0 sutures on a small, noncutting needle. The suture lines were well-concealed within the intralabial creases bilaterally (Figure 3). Care was taken not to denude the clitoral body and to conceal the incision lines. The procedure was executed bilaterally (Figure 3). No intraoperative or postoperative (short- or

long-term) complications were observed. Negligible bleeding was observed intraoperatively.

Postoperatively the patient reported minimal discomfort, which was managed predominantly with external application of Dermoplast, an antiseptic and pain-relieving spray (Medtech, Jackson, Wyoming). Acetaminophen, 2 tablets every 4 hours, was used by the patient as needed.

Results

Electronic and manual searches of the literature failed to identify redundant clitoral prepuce reconstruction or a similar surgical intervention. There-

fore, this presentation is the first description in the scientific-clinical literature of the new technique of redundant clitoral prepuce reconstruction.

The patient reported increased sexual desire and frequency. Unexpectedly, her anxiety about her labia minora anatomic aberrations decreased due to the reduction of emotional tension followed by the redundant clitoral prepuce reconstruction. On a scale of 0–10 she scored aesthetic improvement to

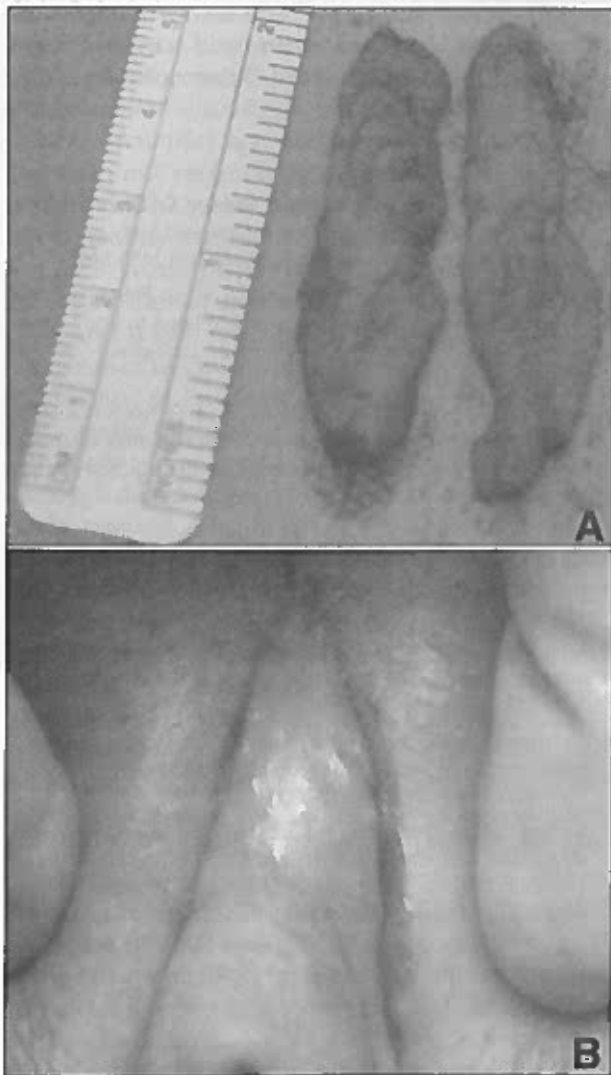


Figure 2 (A) The amount of tissue that was resected bilaterally. (B) An intraoperative view; subcuticular sutures and the incision lines are completely concealed.

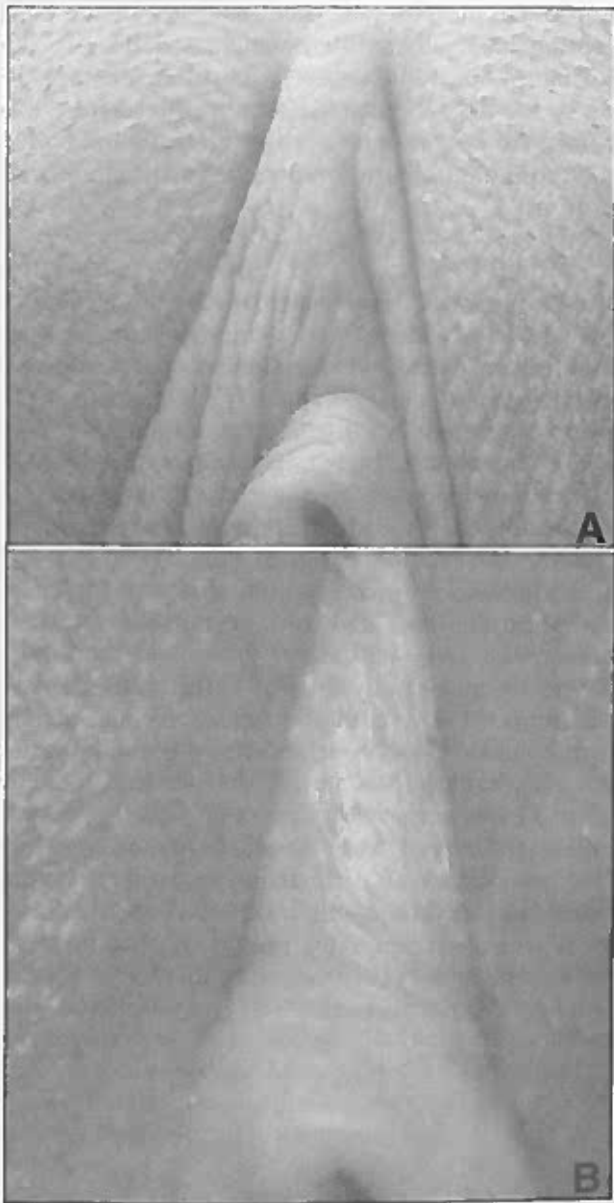


Figure 3 (A) The affected area before the redundant clitoral prepuce reconstruction. (B) The same area 6 months after the redundant clitoral prepuce operation.

be a 10 after the operation (0–3 dissatisfaction with the aesthetic look, 3–6 minimal satisfaction, and 7–10 maximum satisfaction).

After the operation she gave an account for feelings of no regret in each follow-up interval. Her feeling of fear of being negatively evaluated in the area of external genitals subsided. Her sexual desire intensified and frequency of vaginal intercourse increased. The subject noticed that her negative emotional feelings that were directly linked to the anatomic aberration subsided or meaningfully improved and her self-perceived body image perception and self-confidence increased. Her social sexual phobia and anxiety subsided. Postoperatively her degree of satisfaction improved from a 1 before the operation to a 10 on the scale following the redundant clitoral prepuce reconstruction procedure.

Discussion

The findings of this clinical presentation suggest that the newly developed redundant clitoral prepuce reconstruction technique not only rectified existing anatomic aberrations with pleasing aesthetic outcomes, but also improved quality of life and self-perceived body image, intensified sexual desire, and increased frequency of sexual activity. The results of this study support the new concept of this surgical technique, which was easy to execute and was without intraoperative and postoperative complications and had very promising aesthetic outcomes.

The absence of any clinical-scientific data related to redundant clitoral prepuce reconstruction in the existing literature, including the very well-designed and well-executed review article on the labia minora surgery by Liao et al⁵ and the review article on overall cosmetic-plastic gynecology by Ostrzenski,⁶ makes comparison of similarity and differences an impossible task. However, this surgical treatment not only provided pleasing aesthetic results, but also eased the patient's emotional tension (conflict and dilemma) and emotional disturbances.

The redundant clitoral prepuce reconstruction with anterior commissure transposition was executed without significant difficulty. Very promising aesthetic results hold the potential for clinical implementation of this new technique. This surgical intervention has not been adapted from a traditional gynecologic procedure and was developed for aesthetic application. An identifiable weakness of this clinical study is the execution of this surgical method on a single case. However, the results presented here are very important and promising. This presentation documents the need for such a surgical intervention and demonstrates its importance in assisting a woman to attain a positive body image and increase her enjoyment of sexual contact. Therefore, the redundant clitoral prepuce reconstruction surgery is a worthwhile procedure and is in agreement with the American College of Obstetricians and Gynecologists recommendations.⁷

References

1. Jelovsek JE, Barber MD: Women seeking treatment for advanced pelvic organ prolapse have decreased body image and quality of life. *Am J Obstet Gynecol* 2006;194:1455-1461
2. Lowenstein L, Gamble T, Sanses TV, et al; Fellow's Pelvic Research Network: Sexual function is related to body image perception in women with pelvic organ prolapse. *J Sex Med* 2009;6:2286-2291
3. Lowenstein L, Gamble T, Sanses TV, et al; Fellow's Pelvic Research Network: Changes in sexual function after treatment for prolapse are related to the improvement in body image perception. *J Sex Med* 2010;7(2 Pt 2):1023-1028
4. American College of Obstetrics and Gynecology: ACOG Committee Opinion No. 390, December 2007. Ethical decision making in obstetrics and gynecology. *Obstet Gynecol* 2007; 110:1479-1487
5. Liao LM, Michala L, Creighton SM: Labial surgery for well women: A review of the literature. *Int Br J Obstet Gynaecol* 2010;117:20-25
6. Ostrzenski A: Cosmetic gynecology in the view of evidence-based medicine and ACOG recommendations: A review. *Arch Gynecol Obstet* 2011;284:617-630
7. Committee on Gynecologic Practice, American College Obstetricians and Gynecologists: ACOG Committee Opinion Number 378: Vaginal "rejuvenation" and cosmetic vaginal procedures. *Obstet Gynecol* 2007;110:737-738